

# **Deposition of growth layer groups in dentine tissue of captive common dolphins**

## *Delphinus delphis*

Sinéad Murphy<sup>1,2</sup>, Matthew Perrott<sup>3</sup>, Jill McVee<sup>4</sup>, Fiona L. Read<sup>5</sup> & Karen A. Stockin<sup>2</sup>

<sup>1</sup>Institute of Zoology, Zoological Society of London, Regents Park, London, NW1 4RY, UK

<sup>2</sup>Coastal-Marine Research Group, Institute of Natural Sciences, Massey University, Private Bag 102 904, Auckland, New Zealand

<sup>3</sup>Institute of Veterinary, Animal and Biomedical Sciences, Massey University, Private Bag 11 222, Palmerston North, New Zealand

<sup>4</sup>Histology Department, Bute Medical School, University of St Andrews, St Andrews, Fife, KY16 9TS, UK

<sup>5</sup>ECOBIMAR, Instituto de Investigaciones Marinas (CSIC), Eduardo Cabello 6, 36208, Vigo, Spain

\* Corresponding author - e-mail: [sinead.murphy@ioz.ac.uk](mailto:sinead.murphy@ioz.ac.uk); Tel.: +44 (0) 20 7449 6332; fax: +44 (0) 20 7483 2237

### **ABSTRACT**

Knowledge of age structure and longevity (maximum age) are essential for modelling marine mammal population dynamics. Estimation of age in common dolphins (*Delphinus* spp.) is primarily based on counting Growth Layer Groups (GLGs) in the dentine of thin, decalcified and stained sections of teeth. An annual incremental deposition rate was validated for *Delphinus* spp. 30-years ago through the use of tetracycline. However, it is not known if the pulp cavity becomes occluded in older individuals or GLGs continue to be deposited in dentine tissue. To investigate the deposition of GLGs in dentine tissue, teeth samples were obtained during the necropsies of two short-beaked common dolphins (*Delphinus delphis*) that were held in captivity for 31 and 33 years in New Zealand. Individuals were captured together in Hawkes Bay, North Island, New Zealand and classified as juveniles based on physical appearance. Teeth were processed in two ageing laboratories, using four different bone decalcifiers, two sectioning techniques incorporating the use of both a freezing microtome (-20°C) and paraffin microtome, and two different stains. An age was estimated for one of the dolphins, in line with that proposed based on estimated age at capture and period in captivity. However, a hypomineralised area was observed in the dentine tissue close to the pulp cavity of the second individual, preventing estimation of maximum age. The presence and structure of this anomaly is explored further within the study.

### **INTRODUCTION**

Age provides important information on an individual's life history including growth and development, both sexually and physically. Knowledge of age structure and longevity (maximum age) are essential for modelling marine mammal population dynamics. In addition, the ability to estimate age of free-ranging dolphins can provide pertinent information on fluctuations of

Murphy S, Perrott M, McVee J, Read FL and Stockin KA (2014) Deposition of growth layer groups in dentine tissue of captive common dolphins *Delphinus delphis*. NAMMCO Scientific Publications, Volume 10. doi: <http://dx.doi.org/10.7557/3.3017>

mortality rates within birth cohorts. Common dolphins (*Delphinus* spp.) possess small, slightly curved conical homodont teeth, composed of three hard tissue types; enamel, dentine and cementum. The neonatal line, a hypocalcified band in the dentine, is laid down at birth and is thought to be caused by hormonal stress due to abrupt environmental and nutritional changes (Avery 1976, Lockyer 1995, Danil 2004). It delineates the pre- and post-natal dentine tissue, and after which the first incremental layer or Growth Layer Group (GLG) begins to be deposited. GLGs may be recognised by their cyclic repetition and must involve at least one change that can be defined as a countable unit representing, for most species, a 1-year period (Klevezal 1980, Perrin and Myrick 1980, Scheffer and Myrick 1980, Myrick 1998, Murphy *et al.* 2012). In decalcified and stained sections of small delphinid dental tissue, GLGs are composed of two components in post-natal dentine: (1) a broad layer of intermediate optical density and (2) a thinner more translucent layer. This is as a result of variations in the content and distribution of the mineral component, e.g. hydroxyapatite, in dental hard tissues producing differences in optical density and stainability (Klevezal 1980, Luque 2008). In more recent GLGs in older individuals, the opaque layer becomes more compressed and the translucent layer appears proportionally more prominent (Perrin and Myrick 1980). As common dolphins have small teeth, dentine deposition may occlude the pulp cavity before an animal dies (Gurevich *et al.* 1980), though this has not been investigated in individuals of known-age.

A number of different methods have been used to calibrate the GLG deposition rate in small delphinids, by assessing layering patterns in: (1) teeth obtained from captive-born and therefore known-age dolphins (Myrick and Cornell 1990; and references therein); (2) multiple tooth extraction from either captive or free-ranging dolphins over a defined period of time (Hui 1978, Hohn *et al.* 1989); or (3) teeth of captive dolphins with tetracycline 'time marked' labels (Myrick *et al.* 1984, Myrick *et al.* 1988, Myrick and Cornell 1990, Myrick 1998). An annual incremental deposition rate was validated for *Delphinus* spp. 30-years ago by Gurevich *et al.* (1980) through the use of tetracycline, an antibiotic that was employed as a fluorescent vital marker in teeth of captive dolphins. Estimation of age in common dolphins is primarily based on counting GLGs in the dentine (Murphy and Rogan 2006, Danil and Chivers 2007, Westgate and Read 2007, Murphy *et al.* 2009) rather than the cementum tissue, as the latter can be too thin to allow resolution of GLGs (Perrin and Myrick 1980). Danil *et al.* (2004) did use counts of GLGs in the cementum for verification of GLG based estimates in dentine tissue, though actual results of this comparison in accumulation of incremental layers was not presented. Although an annual GLG deposition rate in dental tissue was identified for *Delphinus* spp., it is not known if the pulp cavity becomes occluded in older individuals or if GLGs continue to be deposited in dentine

tissue. To investigate the deposition rate of GLGs in dentine tissue, teeth samples were obtained during the necropsies of two New Zealand common dolphins, later identified as *Delphinus delphis* based on cranial morphology (Jordan 2012). Teeth were processed in two ageing laboratories using a number of different decalcifiers, and preparation methods. Thus within the current study, comparisons of age estimation techniques for common dolphins was also undertaken.

## **MATERIALS AND METHODS**

Two common dolphins, named *Shona* and *Kelly*, were captured off Port Napier, Hawkes Bay, North Island, New Zealand on the 13<sup>th</sup> December 1974. Both individuals were removed on the same day, though at different times of the day, and housed at Marineland, Napier for their entire period in captivity. Further details on the facility and enclosure can be found in Kyngdon *et al.* (2003). Individuals were classified as juveniles based on physical appearance. Kastelein *et al.* (2000) estimated the birth date of both individuals using body length, weight, condition of teeth, general body condition and (length, weight) data from eight common dolphins caught in the eastern tropical Pacific (see André *et al.* 1990). *Shona* and *Kelly* were first measured in 1987, 13 years post-capture, though they were first weighed in 1978. At the time of capture, Kastelein *et al.* (2000) estimated ages of c.4 and c.3 years for *Shona* and *Kelly*, respectively - though it was stated that ages may be over estimated by one to two years. *Shona* and *Kelly* died on the 7<sup>th</sup> April 2006 and 11<sup>th</sup> September 2008, respectively, spending almost c.31 and c.34 years in captivity.

Approximately ten teeth were extracted during post-mortem examinations, comprising of the least worn/curved teeth, and stored either frozen or in 70% ethanol for further analysis. Depending on the degree of tooth wear, samples were primarily selected from the middle of the lower jaws/mandibles, as the largest most uniformly layered teeth are found within this region (Hui 1978). In addition, Gurevich *et al.* (1980) noted that dental layering may cease earlier in maxillary than mandibular teeth.

### **Teeth processing techniques**

Teeth were processed in two ageing laboratories using four different bone decalcifiers, two sectioning techniques incorporating the use of both a freezing microtome (cryostat) (-20°C) and a paraffin microtome, and two different histological stains as detailed herein.

#### *Histology laboratory 1*

Fixation and decalcification: Teeth were cleaned and fixed in 10% neutral buffered formalin at a tissue to solution volume ratio of 1:10 for two weeks. Two decalcification solutions were used: (1) Formical-4™, a fixative

decalcifier supplied by Decal®, and (2) the rapid decalcifier RDO®, a commercial acid mixture produced by Apex Engineering Product Corporation. Formical-4 is a combination of formic acid, formaldehyde, and EDTA (Ethylene-diamine-tetra-acetic acid) and the primary agent in RDO is hydrogen chloride in aqueous solution. Mechanical agitation of tissues in the solutions is recommended during the decalcification process. Teeth were washed in slow running tap water prior to decalcification to remove as much fixative as possible, the period of time depended on the type of decalcifier used. This consisted of three to four minutes for Formical-4 and 24 hours for RDO – the latter should not be combined with formaldehyde as this may result in the potential release of toxic gases. For effective decalcification, bone samples should not be more than 4-5mm thick. Maximum width of teeth from *Shona* and *Kelly* were approximately 4 and 3 mm, respectively.

Teeth were transferred into containers containing either Formical-4 or RDO at a tissue to solution volume ratio of 1:20. Tissue samples were checked for decalcification by determining pliability, or undertaking a chemical endpoint indicator test. The ammonium oxalate turbidity test assessed if calcium was present within the used decalcifying solution (after Luna 1992, RDO 2012). The endpoint test also determined if the decalcification solution was exhausted. 5 ml of the decalcifying solution from the bottom of the specimen container (avoiding picking up particles in the pipette) was added to a 30 ml tube containing a pH indicator strip. Approximately 5 ml of ammonium hydroxide was pipetted into the tube, neutralising the solution as indicated by the pH strip. Subsequently, 5 ml of ammonium oxalate was added to the tube. If the test aliquot was clear after 30 minutes, decalcification was completed. If cloudy, the solution was exhausted, indicated by the precipitated calcium oxalate, decalcification was not complete and the solution was changed (Luna 1992, RDO 2012). Following the decalcification process, teeth were rinsed in water overnight to remove any residues of the acid solution. Teeth were then stored in 70% alcohol.

#### Wax embedding technique

Teeth were initially placed in containers with 70% alcohol and 4% phenol for a period ranging between two-three days and one week, depending on the tooth size. Phenol was used to soften the teeth, as during preliminary trials of the wax embedding technique, teeth became too brittle and were dislodged from the paraffin wax block during sectioning. Teeth were further dehydrated (at room temperature) through increasing concentrations of alcohol; including 70% alcohol (1 hour), 96% alcohol (1 hour), absolute alcohol (1.5 hours), a mixture of 50/50 absolute alcohol/methyl benzoate (2 hours), methyl benzoate (3 hours), and finally chloroform (1 hour) for clearing purposes. Teeth were embedded in paraffin wax and sectioned at 5µm using a Leitz Microtome equipped with a steel histology knife. Longitudinal sections were

obtained from the tooth, by cutting in the buccolingual plane or perpendicular to the mandible, i.e. dolphin cut. Initial sections were discarded, and a series of sections were taken from the centre of the tooth. At this stage, if the tooth was not fully decalcified, Mollifex™, a commercial tissue softener containing glycerol, phenol, acetone and alcohol, was applied to the cut surface of the paraffin block.

Teeth sections were mounted onto polysine slides, for improved tissue adhesion, transferred to a hotplate for 2 h and following this, kept overnight in a 37°C oven. Teeth were stained using 60% Harris' haematoxylin for two-three days, or overnight in 100% haematoxylin. Sections were dipped in a 0.2% acid alcohol solution and blued in Scott's Tap water. Tooth sections were rinsed in running water, dehydrated using 100% alcohol, cleared in xylene and permanently mounted with DPX and a coverslip.

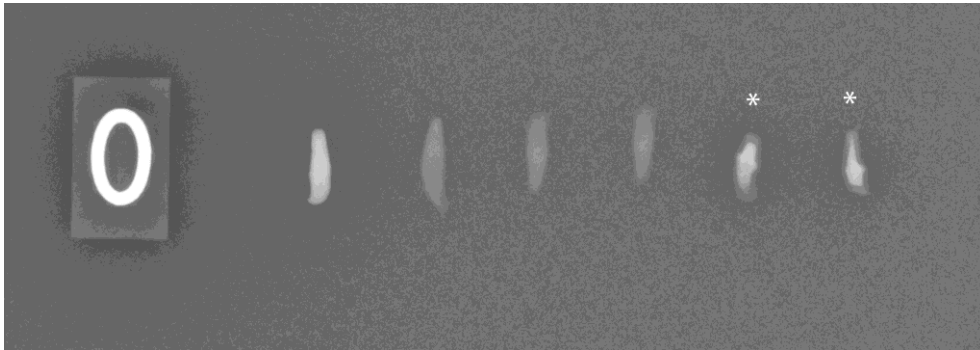
#### *Histology laboratory 2*

Fixation and decalcification: Teeth were adequately fixed in 10% neutral buffered formalin, rinsed in tap water for up to 24 hours, and decalcified in 10% unbuffered formic acid (pH ~1.6). Endpoints for calcium removal were determined by the ammonium oxalate turbidity test (as above). Decalcified teeth were rinsed in water for at least one hour, and often overnight.

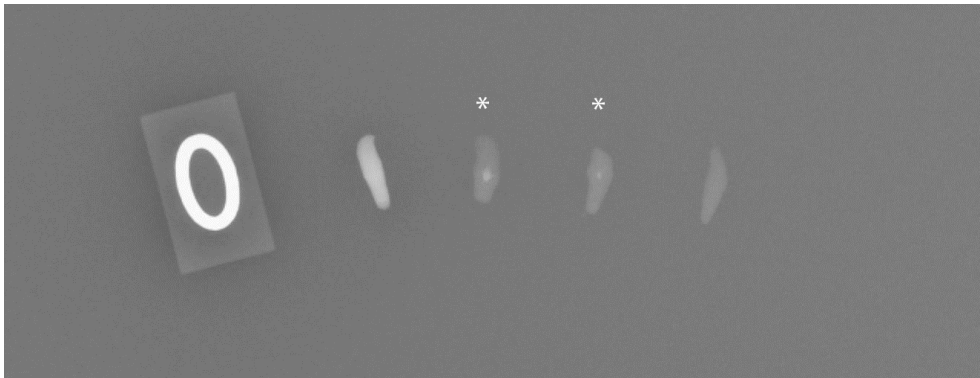
Freezing microtome technique: Teeth were mounted using OCT embedding compound (Tissue-tek® -Sakura) onto a specimen holder and frozen to -20°C in a Leica Jung CM1800 cryostat. Sections 18–25 µm in thickness were cut along the longitudinal axis of the tooth, and all sections from the centre of the tooth were selected. These were then placed in histological cassettes and immediately transferred into the staining solution of 0.2% toluidine blue (pH 8.4) for 10–15 minutes (at room temperature). Sections were rinsed and positioned on superfrost plus slides (Menzel Glaser), left to dry (> 10 minutes) and dehydrated in 70% ethyl alcohol (EtOH) (30 seconds), 95% EtOH (30 seconds), 100% EtOH (30 seconds), and xylene (30 seconds). Sections were then mounted using Entellan resinous medium (ProScitech).

Following trials of 10% formic acid as a decalcifier, a second decalcification solution of 10% EDTA in 0.1 M PBS (pH 7.0) was employed together with radiological endpoint testing (Fig. 1). When calcium was no longer detected by radiography, in comparison with a matched non-decalcified tooth, the tooth was sectioned, stained with toluidine blue and mounted as described above.

**a)**



**b)**



**Fig. 1.** Radiology end point testing of *Shona's* teeth **(a)** after three weeks in 10% EDTA, changing the solution every 3-4 days and **(b)** after an additional two weeks in 10% EDTA. *Shona's* teeth are highlighted by asterisks and weighed approximately 120 g prior to decalcification.

### **Age readings**

Teeth sections were examined by the first author under a Zeiss Axiostar Plus light microscope (x25-400 magnification) for deposition of GLGs within the postnatal dentine tissue. Multiple digital images, at varying magnifications, were obtained using a canon PowerShot G6 (7.1 megapixel) digital camera attached to the light microscope and also an Olympus BX51 microscope and XC50 digital camera system (x12.5, x40, x100 x400 magnification). Pictures of the pulp cavity region were obtained at x400 magnification. Digital images were enhanced by adjusting tone and contrast using Adobe Photoshop CS4. Images were read blind, i.e. without prior knowledge of body length or sex, by a second *Delphinus* ageing expert (FLR). Multiple readings were obtained by each reader and GLGs were marked on digital images by both readers to allow inter-reader comparisons to be made.

### **Mineral content of teeth**

One cleaned tooth sample from both *Shona* and *Kelly* were embedded in a two-component epoxy resin produced by EPO-TEK® (using a combination of Part A and Part B (4:1 ratio)). The resin was left to harden for 24 hours at room temperature. The epoxy embedded teeth samples were then ground with a Struers Discoplan-TS, fitted with a diamond cup wheel and a vacuum holder for simultaneous grinding. This produced a longitudinal half-section, with an exposed pulp cavity. The tooth sample was further ground using P600 sandpaper, and polished using P1200 sandpaper and 0.3 µ Linde-A (aluminium oxide A) to remove scratches that may cause contrast variations. The tooth sample was kept moist during all stages of grinding and polishing to ensure the chemical composition was not altered due to overheating. In addition, after each grinding and polishing stage, the epoxy embedded sample was placed in an ultrasonic water bath for removal of fine particles. Polished samples were then carbon coated, and the mineral content/chemical composition was measured by Energy-Dispersive Spectroscopy (EDS) at Massey University.

## **RESULTS**

*Shona* measured 206 cm in body length, and exhibited signs of atrophy within skeletal muscle tissue, with a dorsal blubber layer depth of 13 mm and a body weight of 74 kg. Mortality was attributed to congestive heart failure. A combination of liver and heart disease led to severe weakness and cardiovascular collapse with either direct pulmonary oedema, or drowning (Massey University, unpubl. data). All mandibular teeth were worn to the gum line on both sides, as well as all teeth in the left maxillae. The first 12 teeth in the right maxillae were partly worn or damaged and the remaining teeth were worn to the gum line. Due to tooth wear, teeth samples were obtained from the middle of the lower left and upper right jaws for analysis.

GLG counts for teeth from the left and right maxillary bones were 43 and 41, and from the left and right mandibular bones were 42 and 41, respectively.

*Kelly* measured 204.5 cm in body length and died in good nutritional condition, with a c.20 mm blubber layer depth and body weight of 95 kg. Cause of death was attributed to anaemia due to chronic gastrointestinal ulceration, and gastric impaction secondary to outflow obstruction (Massey University, unpubl. data). Teeth were worn to the gum line in the first 11 and 10 maxillary teeth on the right and left hand sides, respectively, and the first 25 teeth in both mandibles. The majority of the remaining teeth were partially worn, damaged or broken. Due to tooth wear, teeth were obtained from the mid-to-dorsal aspect of the right mandible. GLG counts from teeth from the maxillary bone were 45 for both the left and right side, and from the left mandible were 49. Teeth were extracted prior to obtaining tooth count data for the right mandible.

### **Age estimations**

#### *Shona*

Eight teeth were processed using four different decalcifiers, including both acids and a chelating agent. These included two commercial decalcifiers, RDO and Formical-4, and two standard laboratory decalcifiers, 10% formic acid and 10% EDTA (Table 1). As can be observed in Figure 2, teeth decalcified using Formical-4 produced the best age estimates. Sections decalcified using RDO (for an extended period, up to 3 days) were poorly stained using a commercially produced Harris' haematoxylin, which affected the clarity of the observed GLGs and consequently the accuracy of age estimations. Only minimum age estimates were obtained using 10% formic acid as the centre of the tooth/region around the pulp cavity was not fully decalcified, even though chemical endpoint testing was employed. On further assessment, laboratory 2 identified calcium deposits in regions around the pulp cavity using the Von Kossa method. Subsequently, 10% EDTA and radiology endpoint testing were employed.

Although teeth were worn, the neonatal line was still present in dental tissues of all processed teeth from both dolphins, thus enabling estimation of age. Based on sections of teeth decalcified using Formical-4 (and wax embedded), age and age ranges estimated for *Shona* by Reader 1 were 32 year and 30-34 years, respectively. For Reader 2, age and age ranges for *Shona* were 31 year and 30-32 years, respectively. Although age ranges overlapped between readers, the slight inconsistency in the estimated age possibly resulted from the differing reading planes, i.e. examined under a microscope by Reader 1, and using digital images by Reader 2. For comparisons, both readers marked each reference GLG on digital images, and inconsistencies primarily existed



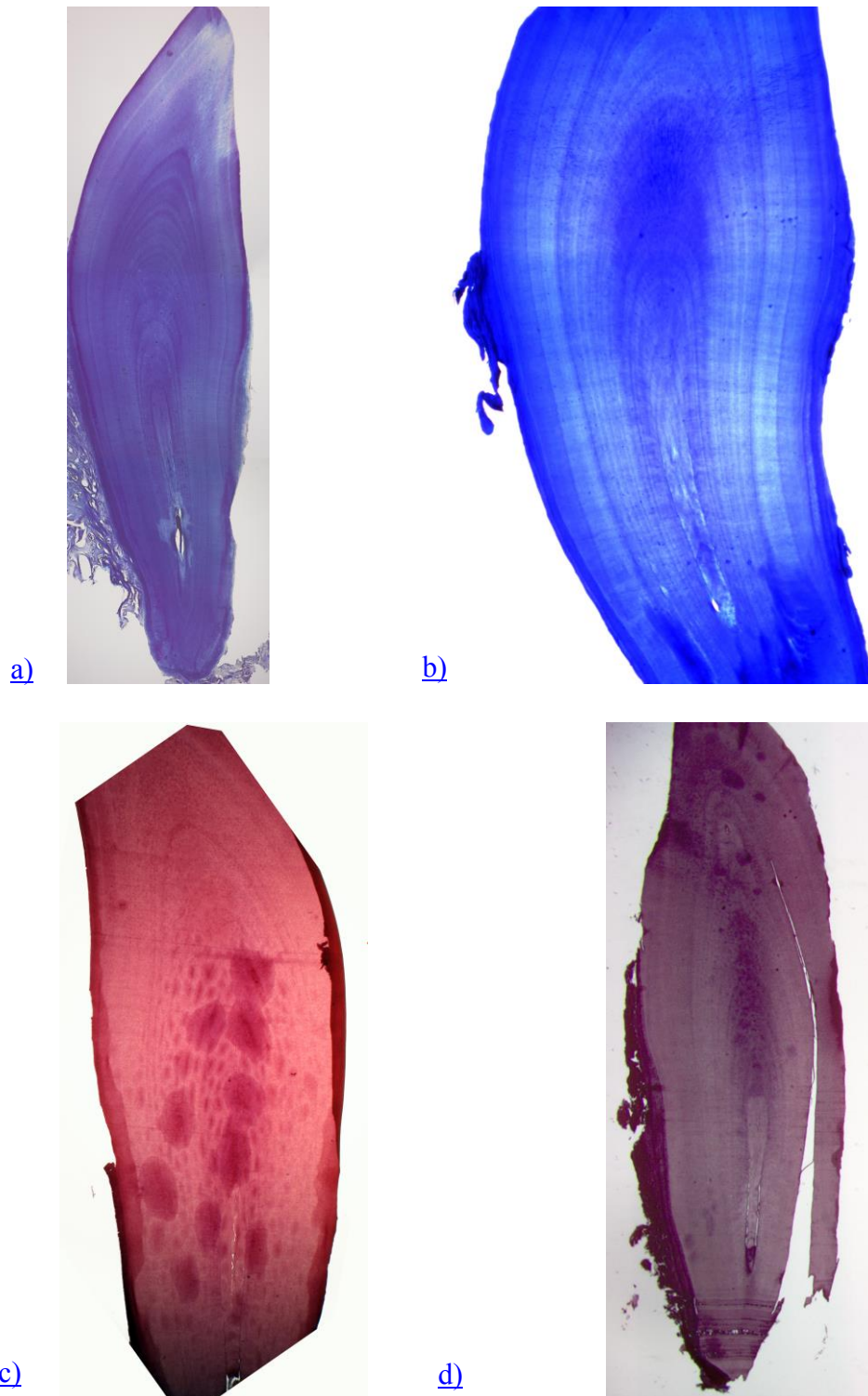
**Table 1.** Decalcifiers evaluated within the current study

<b>Decalcifier</b>	<b>Type</b>	<b>Endpoint test</b>	<b>Decalcification period</b>
RDO®	Inorganic/ mineral acid	Pliability or Ammonium oxalate endpoint test	Up to 3 days
10% Formic acid	Organic acid	Ammonium oxalate endpoint test	4-6 weeks
10% EDTA	Chelating agent	Radiology	> 6 months
Formical- 4™	Combination of formic acid, formaldehyde and EDTA	Ammonium oxalate endpoint test	4-6 weeks

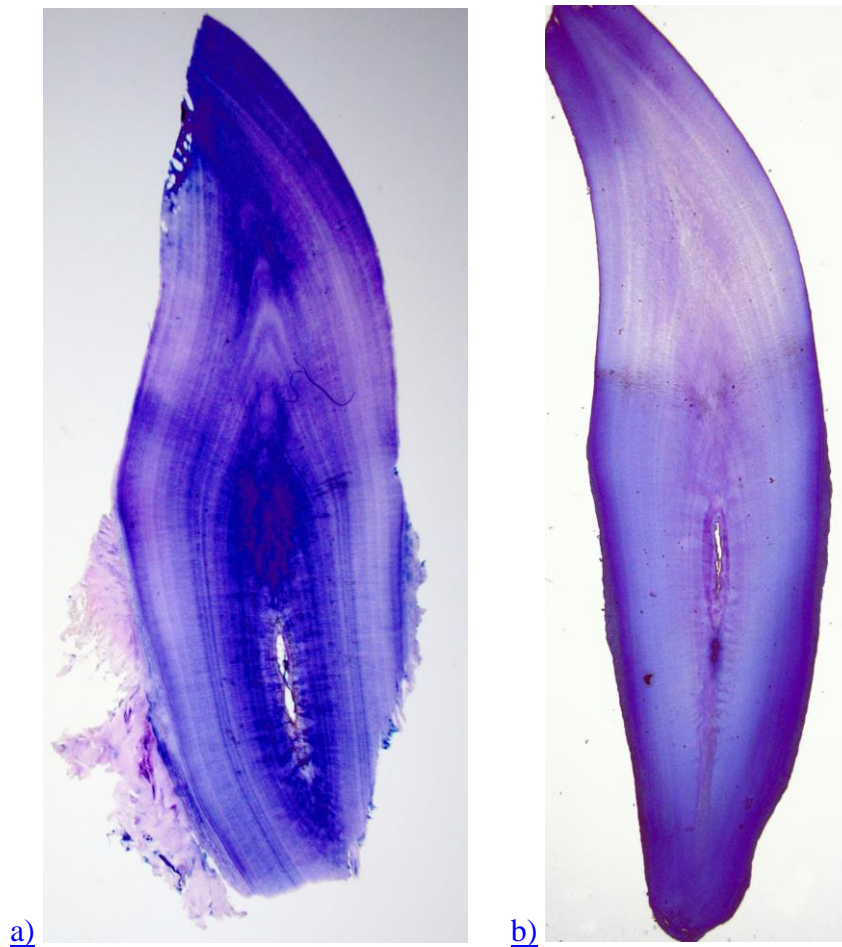
in the most recent GLG adjacent to the pulp cavity. This was resulting from the pulp cavity being virtually occluded and subsequent difficulties in deciphering the smaller newer GLGs. In addition, in the digital images there were difficulties in following younger GLGs along the side of the tooth due to poor uptake of the haematoxylin stain. For the other techniques, a maximum age of >13 years and >20 years were estimated using the freezing microtome and decalcifiers 10% formic acid and 10% EDTA, respectively. A maximum age of >20 years was determined using RDO and the wax embedding technique.

*Kelly*

Only minimum age estimates of 10 and 23 years were obtained using RDO and the wax embedding technique and 10% Formic acid and the freezing microtome technique, respectively. ‘Consensus counts’ were achieved between Readers. As a ‘mineralised’ zone surrounding the pulp cavity was visible within thin sections obtained using both RDO and 10% formic acid, further investigations using 10% EDTA, radiology endpoint testing and the freezing microtome technique were undertaken to assess if this was resulting from a lack of decalcification. Using this methodology, X-rays verified that all the calcium had been removed from the tooth. However, the zone of ‘anomalous tissue’ surrounding the pulp cavity was still present and a minimum age of 21 years was estimated by both Readers (see Fig. 3).



**Fig.2.** Thin sections of teeth from *Shona*; (a) decalcified using 10% Formic Acid, sectioned at 25  $\mu$  using a cryostat and stained using toluidine blue (x40 magnification); (b) decalcified using 10% EDTA, sectioned at 25  $\mu$  using a cryostat and stained with toluidine blue (x40 magnification); (c) decalcified using RDO, wax embedded and sectioned using a microtome at 5 $\mu$  and stained using haematoxylin (x25 magnification) ; and (d) decalcified using Formical-4, wax embedded and sectioned using a microtome at 5 $\mu$  and stained using haematoxylin (x12.5 magnification).



**Fig. 3.** Abnormality surrounding the pulp cavity of *Kelly's* teeth that occurred to varying degrees in the seven processed teeth samples; [\(a\)](#) tooth A, decalcified using 10% formic acid, sectioned at 25  $\mu$  using a cryostat and stained with toluidine blue (x12.5 magnification); [\(b\)](#) tooth B, decalcified using 10% EDTA, sectioned at 25  $\mu$  using a cryostat and stained with toluidine blue (x12.5 magnification).

GLGs were not read in the cementum of sections from either Shona or Kelly due to poor condition of the tissue, as found in other studies on this species.

#### **Mineral composition of dental tissue**

The anomaly surrounding the pulp cavity in all teeth processed from *Kelly* to date (n=7) – anomaly observed to varying degrees - was further assessed by estimating the composition (weight percentages) of calcium (Ca) and phosphorus (P) in teeth from both individuals, for comparisons. As demonstrated in Table 2 and Figure 4, lower Ca and P levels were observed within different regions of *Kelly's* tooth. GLGs adjacent to the pulp cavity

(areas 3 and 4) had lower Ca and P levels compared to previously deposited GLGs (areas 1 and 2, see Figure 4, Table 2). Conversely, no substantial differences in Ca or P levels were observed in different regions of *Shona's* tooth (Fig. 4).

## DISCUSSION

### Teeth processing methodologies

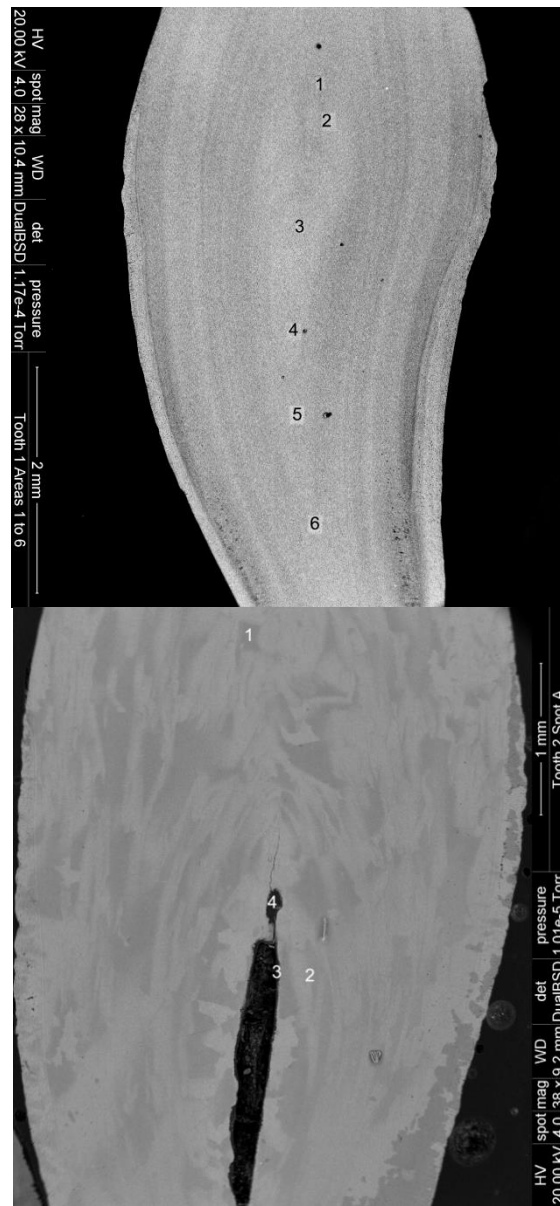
Methodologies varied between ageing laboratories based in the United Kingdom and New Zealand for varying reasons; (1) due to available equipment, (2) ongoing laboratory practices, and most importantly (3) for a comparison of techniques, including the use of decalcifiers, sectioning apparatuses, and histological stains.

#### *Decalcifiers*

All 15 teeth were adequately fixed prior to decalcification as this reduces potential tissue damage during the decalcification process. Due to the age of both individuals (>30 years) and the nature and small (stubby) size of the teeth, difficulties were encountered in removing the relatively high density of calcium deposits that accumulated within the dental tissue, without disturbing the underlying structure of the GLGs.

For age estimation purposes, good decalcifying agents should (1) remove all calcium, (2) preserve cellular detail, (3) not affect staining, and (4) have a short processing/decalcification time. The main active ingredient in RDO is hydrochloric acid, a strong mineral (inorganic) acid that ionizes and dissolves calcium salts. RDO works relatively quickly, i.e. removes large quantities of calcium at a rapid rate, but can damage cellular morphology and affect staining if over-decalcified (RDO 2012). Formic acid, an organic acid, acts more slowly than mineral acids and requires an acidic environment (pH 1.6-1.8) for effective decalcification. As formic acid is less harsh on cellular properties, in comparison to mineral acids, partial over decalcification should result in fewer detrimental effects to staining properties or tissue morphology (Callis 2008).

EDTA is a chelating agent that binds calcium ions at a neutral pH. Decalcification can be a relatively slow process as it penetrates the tissue poorly, though this should have a less deleterious impact on the tissue morphology compared to both mineral and organic acids. However, within the current study both 10% formic acid and 10% EDTA had similar decalcification times of four to six weeks. As chemical endpoint tests are not recommended for EDTA, radiology endpoint testing was employed. Formical-4, composed of a combination of formic acid, formaldehyde and



**Fig. 4.** Sampling locations of calcium and phosphorus in cross sections of teeth from (a) *Shona* and (b) *Kelly*. See Table 3 for weight percentage values measured using energy-dispersive spectroscopy.

**Table 2.** Composition (weight percentages) of calcium (Ca) and phosphorus (P) in different regions of dental tissues from *Shona* and *Kelly*. See Fig. 4 for location of areas.

wt%	Area 1	Area 2	Area 3	Area 4	Area 5	Area 6
<i>Shona</i>						
Ca	24.32	24.95	25.55	20.08	20.2	19.97
P	12.43	12.83	12.97	10.41	10.43	10.35
<i>Kelly</i>						
Ca	25.28	39.45	1.06	0.95		
P	13.2	17.49	0.28	0.41		

EDTA, is a fixative decalcifier. Samples can be placed directly into this solution without prior fixation, with the primary aim of shortening the processing times. As noted in Table 1 however, decalcification using this commercial solution can be a relatively slow process. While Formical-4 produced the best sections of *Shona*'s teeth for age estimation, future work on common dolphins will not focus on the use of this decalcifier due to the extended decalcification period - unless the individuals in questions are of an older age and only minimum age estimates are obtained using other methodologies.

Time required for decalcification was determined, depending on the type of decalcifier used (see Table 1), by manual assessment of pliability, calcium oxalate precipitation endpoint tests and radiography. On general agreement, X-rays are the most accurate method for determining the endpoint, followed by chemical and physical testing (Callis 2008). However, X-rays are a relatively expensive option, and within the current study chemical endpoint testing was not found to be consistently reliable as some calcium deposits remained present upon sectioning, despite the ammonium oxalate test indicating all calcium had been removed. This was also observed using a larger sample of teeth from stranded NZ common dolphins, and in a previous study ageing monk seal (*Monachus monachus*) dental tissues (Murphy *et al.* 2012). Determining pliability through bending the specimen is less accurate than chemical testing, and can potentially damage samples.

RDO is the primary decalcifying agent used to date in marine mammal age estimation studies (e.g. Myrick *et al.* 1983, Lockyer 1993, 1995, Hohn and Fernandez 1999, Gibbens and Arnould 2009, Luque *et al.* 2009, Dellabianca *et al.* 2011), including those on common dolphins (Murphy and Rogan 2006, Danil and Chivers 2007, Westgate and Read 2007), due to its short decalcification time. Based on the current analysis, it is recommended that for individuals of an age greater than 25 years (determined from an initial age

estimation assessment or where minimum age is known), that alternative decalcifiers are used as extended periods of time within the harsh RDO solution - up to 3 days, due to the high density of calcium deposits in these older individuals – possibly resulted in poor tissue staining (see Fig. 2c). However, it cannot be ruled out that this may have occurred by using the commercially produced Harris' haematoxylin, whereas better results may have been obtained using a laboratory prepared Erlich's haematoxylin (such as in Murphy and Rogan 2006). In cases where edges of the tooth can be sectioned using a scalpel blade prior to decalcification, to expose as much of the centre of the tooth as possible to the decalcification solution, RDO may well be of potential use. Though it should be noted that the slices must be even and continuous, otherwise sectioning is difficult. Grinding could be an alternative approach.

#### *Processing techniques and staining*

The differing methodologies resulted in varying section thicknesses of 5 µm using a Leitz microtome (wax embedding) and 18–25 µm for the Leica Jung CM1800 cryostat (freezing microtome). Additional accessory layers can be visible within GLGs of thick sections if teeth are sectioned at a slight angle, which may cause errors in age estimation readings. Accessory layers may overlap each other thus giving the appearance of more layers. Within the current study, minimum age estimates were obtained using the cryostat methodology enlisted by Laboratory 2, though this was attributed to the type of decalcifying agent used and not to section thickness and/or processing technique. Toluidine blue proved a better stain on cryostat processed thick sections within the current study, compared to commercially produced Haematoxylin. Using a larger sample size of teeth from stranded NZ common dolphins, neither were the laboratory prepared haematoxylin, Gill's method (chemical oxidation) or Erlich's method (natural ripening), able to provide the contrast afforded by toluidine blue. This was independent of section thickness and whether or not a progressive versus regressive staining method was employed, suggesting that toluidine blue may have retained better affinity for tissues decalcified using organic acids and chelating agents. However, the opposite has been found in another study on common dolphins using the inorganic acid RDO (Read pers. obs.). The main differences between the wax embedding techniques employed within the present analysis and that of Luque *et al.* (2009) was the usage of xylene within the latter study, a standard clearing agent used within histological practices. Chloroform was used in the present study prior to paraffin embedding, as dental tissue became too brittle for sectioning using xylene – a methodology used for general processing of small cetacean teeth within laboratory 1. In addition, the methyl benzoate double embedding method was employed to ensure that teeth samples did not spend an extended period of time in the alcohol solutions.

**Age estimations of captive dolphins**

A maximum age could only be determined for *Shona* in the current study due to the area of hypomineralisation in *Kelly's* teeth. Based on dental samples, an age of 32 years and an age range of 30-34 were estimated. *Shona* spent 31.3 years in captivity and as noted earlier, estimated age at capture was four years - though this may have been over estimated by one to two years (Kastelein *et al.* 2000). This all suggests that *Shona* ranged between 33 and 35 years in age. Although these ages are within the estimate age ranges from dental samples proposed for the animal, the difficulties in deciphering newer GLGs adjacent to the pulp cavity, the pulp cavity being virtually occluded, and the poor staining/lack of contrast within all GLGs, incorporated a certain degree of error into the readings. To date, the oldest aged wild common dolphin was estimated to be over 30 years old, though a maximum age or age range was not determined for this animal (Westgate and Read 2007). All maximum ages reported in other common dolphin populations world-wide were  $\leq 30$  years (see Table 3).

**Table 3.** Maximum age estimates for common dolphin populations worldwide.

Location	Species	Age (yrs)	Reference
Black Sea, Turkey	<i>D. delphis ponticus</i>	28	(Amaha 1994)
Northeast Atlantic	<i>D. delphis</i>	30	(Collet 1993, Murphy et al. 2010)
Northwest Atlantic	<i>D. delphis</i>	>30	(Westgate and Read 2007)
Gulf of California, Mexico	<i>D. capensis</i>	21	(Nino-Torres et al. 2006)
Southeast Brazil	<i>Delphinus sp.</i>	18	(Siciliano et al. 2007)
North Pacific	<i>D. delphis</i>	27	(Ferrero and Walker 1995)
Eastern Tropical Pacific	<i>D. delphis</i>	25	(Danil and Chivers 2007)
Japan	<i>D. delphis</i>	27	(Takahashi et al. 2006)
New Zealand	<i>D. delphis</i>	29	(Stockin et al. 2011)
South Africa	<i>D. capensis</i>	24	(Mendolia 1989)



Results from the current study suggest that the pulp cavity possibly becomes occluded in common dolphins >30 years and this, in addition to errors in reading new GLGs adjacent to the pulp cavity in these older dolphins, may lead to under-estimation of maximum age within populations. It should be noted however that although the “straightest” teeth were sampled, the teeth that were collected from both *Shona* and *Kelly* were stubby, curved and some slightly twisted. These characteristics produced slightly “off centre” sections that may have missed some of the critical areas around the pulp cavity where small GLGs are deposited, thus possibly affecting estimation of maximum age.

### **Hypomineralisation**

The significantly lower levels of calcium and phosphorus adjacent to the pulp cavity in *Kelly*'s teeth suggest either resorption of minerals (Ca and P) from dentine tissue, or mineralization interference, i.e. dentine tissue was not appropriately mineralized. Factors responsible for resorption and repair of dental tissues were initially believed to be only of local origin, with odontoclastic and cementoclastic activity occurring in response to local injury, pressure, disease and malocclusion (Myrick 1988). However, in addition to these local causes, system alteration of dental tissues are believed to occur through regulation of blood-serum calcium (Myrick 1988). Lockyer (1993) argued that resorption is a response to a severe long-term or continuing change in physiological state, probably with hormone imbalance, which either exacerbates any pre-existing hereditary-based tendency or initiates a chronic hypocalcaemia condition.

Mineralisation interference has been defined by Lockyer (1993) as irregularities in the lamina formation, generally found in the pulp cavity edge, resulting in wavy lines, swirl patterns and asymmetry which disrupt usual patterns. In addition, Myrick (1988) noted a strong discontinuity in pattern, or a layer that was especially dark, followed by a gap in layering. This interruption was succeeded by prominent thickened unmineralised predentine. The anomaly in *Kelly*'s teeth did not exhibit the typical ‘scallop’ or ‘convoluted scallop’ appearance identified by Myrick (1988) for moderate and advanced mineralisation interference. Thickened unmineralized predentine was observed in some teeth sections, in addition to wavy lines along tissue margins (see Fig. 3). In other teeth, however, more noticeable internal resorption of minerals around the pulp cavity was evident with obliteration of the pulpal margin, and the presence of a dark stained layer adjacent to the anomaly was also observed. The extensive size of the pulp cavity in some teeth (see Fig. 4b) from an individual of this age - more than 33 years - suggests internal resorption of dental tissue rather than a cessation of dental deposition due to mineralisation interference. In addition, other skeletal bones also exhibited a lower mineral weight/density. For example, *Kelly*'s cranium

weighed less than free-ranging females of a similar condylobasal length (Jordan 2012). Myrick (1988) however reported that resorption generally resulted in actual erosion and frequent repair of existing regular laminated dental tissue, resulting in amorphous and/or globular appearance; frequently with holes, cutting across into regular tissue (Myrick 1988, Lockyer 1995).

The anomaly surrounding the pulp cavity was observed to varying degrees in all eight teeth processed teeth from *Kelly*, suggesting that the anomaly is of systemic and not local origin. The causes for systemic resorption or interference within *Kelly's* skeletal material could be due to a number of reasons such as (a) old age and development of osteoporosis, and/or (b) stress-induced hypocalcaemia. Hypocalcaemia, or low serum calcium, occurs when calcium intake into the blood is exceeded by calcium loss from circulation (Myrick 1988). Serum calcium levels are restored through acquiring calcium from tissues such as extracellular and bone. Elevated cortisol levels can decrease serum calcium, resulting in borrowing of calcium from skeletal material (Myrick 1988), and various external and internal stressors can stimulate the release of cortisol through the hypothalamic-pituitary-adrenal pathway. When bone calcium resorption is greater than deposition, this can lead to osteoporosis and deposition of calcium in soft tissues. This is also a principle sign of ageing.

## ACKNOWLEDGEMENTS

The authors thank present and former employees of Napier Marineland, especially Regan Beckett, Garry MacDonald and Bridey White whom supported the post-mortem examinations and subsequent use of tissues recovered from *Kelly* and *Shona* for research purposes. Additional thanks are extended to colleagues at Massey University for post-mortem examinations and laboratory analysis including Wendi Roe, Brett Gartrell and Mike Hogan (IVABS), Robert Stewart and Anja Möbis (INR), Doug Hopcroft (MMIC at IMBS) and Emmanuelle Martinez (INS). SM was supported by a Marie Curie International Outgoing Fellowship and a Massey University International Visitors Fellowship (IVRF). This research was conducted under research permits RNW/22/2003/182 and RNW/HO/2008/03 issued to KAS by the New Zealand Department of Conservation.

## REFERENCES

- Amaha A (1994) Geographic variation of the common dolphin, *Delphinus delphis* (Odontoceti: *Delphinidae*). Ph.D. Tokyo University of Fisheries, Tokyo.
- André JM, Ribeyre F, and Boudou A (1990) Relations entre l'âge, la longueur totale, le poids total et le poids de organes chez trois espèces de

- dauphins de la zone tropicale Est de l'océan Pacifique. *Mammalia* 54:479-488. doi: <http://dx.doi.org/10.1515/mamm.1990.54.3.479>
- Avery JK (1976) Dentin. In: Bhaskar SN (editor); Orban's Oral Histology and Embryology. Mosby, Saint Louis, 105-140.
- Callis GM (2008) Bone. In: Bancroft JD and Gamble M (eds.); Theory and Practice of Histological Technique 6th Edition. Churchill Livingstone, Elsevier, 333-364.
- Collet A (1993) Age et statut reproducteur des cétacés capturés. Résultats préliminaires et analyses partielles des données 1993. Rapport GERDAU 1993. Rapport Gerdau 1993, CRMM, La Rochelle.
- Danil K (2004) Growth and reproduction of female short-beaked common dolphins, *Delphinus delphis*, in the eastern tropical Pacific. MSc. University of San Diego.
- Danil K and Chivers SJ (2007) Growth and reproduction of female short-beaked common dolphins, *Delphinus delphis*, in the eastern tropical Pacific. *Can. J. Zool.* 85(1):108-121. <http://dx.doi.org/10.1139/z06-188>
- Danil K, Robertson KM and Chivers SJ (2004) An evaluation of using enhanced digital microscopy to estimate ages of short-beaked common dolphins (*Delphinus delphis*). U.S. Dep. Commer., NOAA Technical Memorandum NMFS SWFSC-365.
- Dellabianca NA, Hohn AA and Goodall RNP (2011) Age estimation and growth layer patterns in teeth of Commerson's dolphins (*Cephalorhynchus c. commersonii*) in subantarctic waters. *Mar. Mammal Sci.* 28(2):378-388. doi: <http://dx.doi.org/10.1111/j.1748-7692.2011.00475.x>
- Ferrero RC and Walker WA (1995) Growth and reproduction of the common dolphin, *Delphinus delphis* Linnaeus, in the offshore waters of the North Pacific Ocean. *Fish. Bull.* 93:483-494.
- Gibbens J and Arnould JPY (2009) Age-specific growth, survival, and population dynamics of female Australian fur seals. *Can. J. Zool.* 87(10):902-911. doi: <http://dx.doi.org/10.1139/Z09-080>
- Gurevich VS, Stewart LH and Cornell LH (1980) The use of tetracycline in age determination of common dolphins, *Delphinus delphis*. In: Perrin WF and Myrick Jr. AC (eds.); Age determination of toothed whales and sirenians. International Whaling Commission, Cambridge, 165-169.
- Hohn A and Fernandez S (1999) Biases in dolphin age structure due to age estimation techniques. *Mar. Mammal Sci.* 15(4):1124-1132. doi: <http://dx.doi.org/10.1111/j.1748-7692.1999.tb00881.x>
- Hohn AA, Scott MD, Wells RS, Sweeney JC and Irvine AB (1989) Growth layers from known-age, free-ranging bottlenose dolphins. *Mar. Mammal Sci.* 5(4):315-342. doi: <http://dx.doi.org/10.1111/j.1748-7692.1989.tb00346.x>

- Hui CA (1978) Reliability of using dentin layers for age determination in *Tursiops truncatus*. Final report to the Marine Mammal Commission in fulfillment of contract MM7AC021. Report no. MMC-77/09. .
- Jordan FF (2012) Skull morphometry of the common dolphin, *Delphinus* sp., from New Zealand waters. MSc thesis. Massey University, Auckland.
- Kastelein RA, MacDonald GJ and Weipkema PR (2000) A note on food consumption and growth of common dolphins (*Delphinus delphis*). *J. Cet. Res. Man.* 2(1):69-73.
- Klevezal GA (1980) Layers of the hard tissues of mammals as a record of growth rhythms of individuals. In: Perrin WF and Myrick Jr. AC (eds.); *Age Determination of Toothed Whales and Sirenians*. Reports of the International Whaling Commission, Special Issue 3. Cambridge, 89-94.
- Kyngdon DJ, Minot EO and Stafford KJ (2003) Behavioural responses of captive common dolphins *Delphinus delphis* to a 'Swim-with-Dolphin' programme. *Appl. Anim. Beh. Sci.* 81(2):163-170. doi: [http://dx.doi.org/10.1016/S0168-1591\(02\)00255-1](http://dx.doi.org/10.1016/S0168-1591(02)00255-1)
- Lockyer C (1993) A report on patterns of deposition of dentine and cement in teeth of pilot whales, genus *Globicephala*. In: Donovan GP, Lockyer C and Martin AR (eds.); *Biology of Northern Hemisphere Pilot Whales*. International Whaling Commission, Cambridge, 137-161.
- Lockyer C (1995) A review of factors involved in zonation in odontocete teeth, and an investigation of the likely impact of environmental factors and major life events on harbour porpoise tooth structure. In: Bjørge A and Donovan GP (eds.); *Biology of the Phocoenids*. International Whaling Commission, Cambridge, 511-529.
- Luna LG (1992) *Histopathologic methods and color atlas of special stains and tissue artifacts*, 1st Edition. Johnson Printers, Maryland, 767 pp.
- Luque PL (2008) Age determination and interpretation of mineralization anomalies in teeth of small cetaceans. PhD thesis. University of Vigo, Vigo.
- Luque PL, Learmonth JA, Santos MB, Ieno E and Pierce GJ (2009) Comparison of two histological techniques for age determination in small cetaceans. *Mar. Mammal Sci.* 25(4):902-919. doi: <http://dx.doi.org/10.1111/j.1748-7692.2009.00304.x>
- Mendolia C (1989) Reproductive biology of common dolphins (*Delphinus delphis* Linnaeus) off the south east coast of southern Africa. MSc thesis. University of Port Elizabeth, Port Elizabeth.
- Murphy S, Pierce GJ, Law RJ, Bersuder P, Jepson PD, Learmonth JA, Addink M, Dabin W, Santos MB, Deaville R, Zegers BN, Mets A, Rogan E, Ridoux V, Reid RJ, Smeenk C, Jauniaux T, López A, Farré JMA, González AF, Guerra A, García-Hartmann M, Lockyer C and Boon JP (2010) Assessing the effect of persistent organic pollutants on reproductive activity in common dolphins and harbour porpoises. *J.*

*Northwest Atl. Fish. Org.* 42: 153-173. doi: <http://dx.doi.org/10.2960/J.v42.m658>

- Murphy S and Rogan E (2006) External morphology of the short-beaked common dolphin, *Delphinus delphis*: growth, allometric relationships and sexual dimorphism. *Acta Zool.* 87(4):315-329. doi: <http://dx.doi.org/10.1111/j.1463-6395.2006.00245.x>
- Murphy S, Spradlin T, Mackey B, McVee J, Androukaki E, Tounta E, Karamanlidis A, Dendrinis P, Joseph E, Lockyer C and Matthiopoulos J (2012) Age estimation, growth and age-related mortality of Mediterranean monk seals *Monachus monachus*. *Endan. Species Res.* 16:149-163. doi: <http://dx.doi.org/10.3354/esr00392>
- Murphy S, Winship A, Dabin W, Jepson PD, Deaville R, Reid RJ, Spurrier C, Rogan E, López A, González AF, Read FL, Addink M, Silva M, Ridoux V, Learmonth JA, Pierce GJ and Northridge SP (2009) Importance of biological parameters in assessing the status of *Delphinus delphis*. *Mar. Ecol. Prog. Ser.* 388:273-291. doi: <http://dx.doi.org/10.3354/meps08129>
- Myrick Jr. AC (1988) Is tissue resorption and replacement in permanent teeth of mammals caused by stress-induced hypocalcemia? In: Davidovitch Z (editor); *The biological mechanisms of tooth eruption and roof resorption*. EBSCO Media, Birmingham, 379 - 389.
- Myrick Jr. AC (1998) Some new and potential uses of dental layers in studying *Delphinid* populations. In: Pryor K and Norris KS (eds.); *Dolphin societies*. University of California Press, Berkeley, 251-279.
- Myrick Jr. AC and Cornell LH (1990) Calibrating dental layers in captive bottlenose dolphins from serial tetracycline labels and tooth extractions. In: Leatherwood S and Reeves R (eds.); *The bottlenose dolphin*. Academic Press, New York, 587-608.
- Myrick Jr. AC, Hohn AA, Sloan PA, Kimura M and Stanley DD (1983) Estimating age of spotted and spinner dolphins (*Stenella attenuata* and *Stenella longirostris*) from teeth. La Jolla, CA, NOAA/National Marine Fisheries Service/Southwest Fisheries Science Center, (NOAA Technical Memorandum NMFS, SWFC-3).
- Myrick Jr. AC, Yochem PK and Cornell LH (1988) Toward calibrating dentinal layers in captive killer whales by use of tetracycline labels. *Rit. Fiskideilar* 1:285-296.
- Myrick Jr. AC, Shallenberger EW, Kang I and MacKay DB (1984) Calibration of dental layers in seven captive Hawaiian spinner dolphins, *Stenella longirostris*, based on tetracycline labelling. *Fish. Bull.* 82:207-225.
- Nino-Torres CA, Gallo-Reynoso JP, Galvan-Magana F, Escobar-Briones E and Macko SA (2006) Isotopic analysis of  $\delta^{13}\text{C}$ ,  $\delta^{15}\text{N}$ , AND  $\delta^{34}\text{S}$  “A feeding tale” in teeth of the longbeaked common dolphin *Delphinus*

- capensis*. *Mar. Mammal Sci.* 22(4):831-846. doi: <http://dx.doi.org/10.1111/j.1748-7692.2006.00065.x>
- Perrin WF and Myrick Jr. AC (1980) Age determination of toothed whales and sirenians. Reports of the International Whaling Commission (Special Issue 3). International Whaling commission, Cambridge, 229 pp.
- RDO (2012) [http://www.rdodecal.com/t\\_procedures.html](http://www.rdodecal.com/t_procedures.html) Downloaded on 01.02.12.
- Scheffer VB and Myrick Jr. AC (1980) A review of studies to 1970 of growth layers in the teeth of marine mammals. In: Perrin WF and Myrick Jr. AC (eds.); *Age determination of toothed whales and sirenians*. Reports of the International Whaling Commission (Special Issue 3). Cambridge, 51-61.
- Siciliano S, Ramos RMA, Di Benedetto APM, Santos MCO, Fragoso AB, Brito Jr. JL, Azevedo AF, Vicente AFC, Zampirolli E, Alvarenga FS, Barbosa L and Lima N RW (2007) Age and growth of some delphinids in south-eastern Brazil. *J. Mar. Biol. Assoc. UK* 87(1):293-303. doi: <http://dx.doi.org/10.1017/S0025315407053398>
- Stockin KA, Murphy SN, Duignan PJ, Perrott MM, Jones GW and Roe WD (2011) Reproductive biology of New Zealand common dolphins (*Delphinus* sp). Page 283 in *19th Biennial Conference on the Biology of Marine Mammals*, Tampa Florida, November 27-December 2, 2011.
- Takahashi Y, Ohwada S, Watanabe K, Ropert-Coudert Y, Zenitani R, Naito Y and Yamaguchi T (2006). Does elastin contribute to the persistence of corpora albicantia in the ovary of the common dolphin (*Delphinus delphis*). *Mar. Mammal Sci.* 22(4):819-830. doi: <http://dx.doi.org/10.1111/j.1748-7692.2006.00050.x>
- Westgate A and Read A (2007) Reproduction in short-beaked common dolphins (*Delphinus delphis*) from the western North Atlantic. *Mar. Biol.* 150:1011-1024. doi: <http://dx.doi.org/10.1007/s00227-006-0394-1>