



Criteria for assessing maturity of skulls in the common dolphin, *Delphinus* sp., from New Zealand waters

FRIEDERIKE F. J. JORDAN,¹ Coastal-Marine Research Group, Institute of Natural and Mathematical Sciences, Massey University, Private Bag 102 904, Auckland, New Zealand; SINÉAD MURPHY, Coastal-Marine Research Group, Institute of Natural and Mathematical Sciences, Massey University, Private Bag 102 904, Auckland, New Zealand and Institute of Zoology, Zoological Society of London, Regent's Park, London, NW1 4RY, United Kingdom; EMMANUELLE MARTINEZ, Coastal-Marine Research Group, Institute of Natural and Mathematical Sciences, Massey University, Private Bag 102 904, Auckland, New Zealand and Pacific Whale Foundation, 300 Ma'alaea Road, Wailuku, Hawaii 97653, U.S.A.; CHRISTOPHE AMIOT, Human-Wildlife Research Group, Institute of Natural and Mathematical Sciences, Massey University, Private Bag 102 904, Auckland, New Zealand; ANTON VAN HELDEN,² Museum of New Zealand, Te Papa Tongarewa, Wellington, New Zealand; KAREN A. STOCKIN, Coastal-Marine Research Group, Institute of Natural and Mathematical Sciences, Massey University, Private Bag 102 904, Auckland, New Zealand.

ABSTRACT

Knowledge about the maturity status of specimens included in evolutionary, taxonomic or life history investigations is fundamentally important. This study investigated the use of the degree of cranial suture fusion, the developmental status of cranial bones, and the degree of tooth wear as indicators for cranial maturity status in *Delphinus* sp. from New Zealand waters. In total, 15 sutures, one joint and three nonmetric characters were assessed on 66 skulls obtained from stranded and by-caught individuals sampled between 1932 and 2011. A suture index (SI) was computed based on 10 sutures, in which degree of fusion was correlated with age and the three misclassification indices (MI), calculated for a given suture, were <50%. In addition to these, five premaxilla-maxilla fusion and seven tooth wear categories were assessed. Results suggest that New Zealand *Delphinus* sp. skulls should be regarded as cranially mature if at least two of the following criteria are met: (1) individuals assessed as sexually mature, (2) aged ≥ 11 yr, (3) $SI \geq 8$, and (4) premaxilla-maxilla fusion $\geq 75\%$ of the length of the dorsal side of the rostrum. Presence of any number of rostral teeth worn to the gum line provided further evidence for cranial maturity.

Key words: *Delphinus*, common dolphin, cranial maturity, suture index, premaxilla-maxilla fusion, tooth wear.

Both metric and nonmetric features of the skull are commonly examined as part of evolutionary, taxonomic, ecological, and life history studies of odontocetes

¹Corresponding author (e-mail: friederike.jordan@yahoo.com).

²Raumati South 5032, Wellington, New Zealand.

(Perrin 1975, Rommel 1990, Heyning and Lento 2002, Fordyce 2009, Galatius *et al.* 2011). After attaining sexual maturity, odontocetes typically continue to grow for several years until physical maturity is reached (Chivers 2009). For this reason, it is important that only skulls from physically mature individuals, as determined by the fusion of both epiphyses to the vertebral bodies (Calzada *et al.* 1997), are included for nonontogenetic analyses, since osteological features are not yet fully developed in immature animals (Perrin and Heyning 1993). However, due to the frequent lack of postcranial skeletal material, physical maturity status of cleaned museum skulls is often unknown. In addition, information regarding age, sexual maturity status, and total body length, from which physical maturity status could be inferred, are all too often unavailable. In such cases, only skulls in which growth has ceased and are thus said to have attained cranial maturity, should be included in morphometric examination (Perrin 1975, Perrin and Heyning 1993). Individual skull bones, including the nasals, are loose in young animals and fuse with age (Rommel 1990). Pattern of suture fusion in relation to relative age (based on a suture index, SI) and/or estimated age (based on counting growth layer groups in dental tissue) has been published for various seal species (*e.g.*, Sivertsen 1954, Stewardson *et al.* 2011) and chronological skull growth has been thoroughly documented for spinner and spotted dolphins, *Stenella* sp. (Perrin 1975). Assessment of the degree of ontogenetic fusion of a single cranial suture, the degree of overall cranial suture fusion obtained through the calculation of a suture index, and developmental status of interalveolar septa are commonly employed methods to aid discrimination between cranially mature and immature skulls (*e.g.*, Sivertsen 1954, Van Waerebeek 1993, Westgate 2007, Tavares *et al.* 2010, Chen *et al.* 2011). “Distal fusion” of the maxilla-premaxilla suture has been determined as a reliable indicator for skeletal maturity in several dolphin species including bottlenose dolphins, *Tursiops truncatus* (Mead and Potter 1990), spinner dolphins, *S. longirostris* (Dailey and Perrin 1973), and striped dolphins, *S. coeruleoalba* (Calzada *et al.* 1997). However, fusion at the distal end of the rostrum has been observed in both sexually immature and mature skulls of short-beaked common dolphins, *Delphinus delphis* (Perrin and Heyning 1993) and Pacific white-sided dolphins, *Lagenorhynchus obliquidens* (Walker *et al.* 1986), rendering it an unreliable predictor of cranial maturity in those species. Instead, varying degrees of fusion along the maxilla-premaxilla suture are frequently being used as a criterion for cranial maturity assessment in *Delphinus* sp. studies (*e.g.*, Amaha 1994, Bell *et al.* 2002, Jefferson and Van Waerebeek 2002).

The common dolphin is globally distributed, with populations present in both coastal and oceanic waters, between 60°N and 50°S (Di Natale and Mangano 1983, Jefferson *et al.* 1993, Evans 1994, Heyning and Perrin 1994). Although there is some ambiguity in the phylogenetic relationships and taxonomy (Amaral *et al.* 2012a, b), two morphotypes, the short-beaked-form, *D. delphis*, and the long-beaked-form, *D. capensis*, are currently recognized as two distinct species (Heyning and Perrin, 1994, Rosel *et al.* 1994). Taxonomic status of the New Zealand common dolphin remains unclear, owing to morphometric (Amaha 1994, Jordan 2012) and genetic uncertainty (Stockin *et al.* 2014). Mean rostrum length to zygomatic width ratios (RL/ZW) in New Zealand and Australian common dolphins combined (RL/ZW = 1.5, New Zealand $n = 15$, Australia $n = 9$) fell between the mean ratios recorded for other geographic populations of short- and long-beaked common dolphins (Amaha 1994). Likewise, recent genetic data did not clearly show to which of the two lineages the New Zealand population is

more closely related (Stockin *et al.* 2014). The necessity to conduct further research related to taxonomy and geographic variation of New Zealand *Delphinus* sp. (Stockin 2008, Jordan 2012, Stockin *et al.* 2014) highlights the importance of defining criteria based on which maturity of skulls can be determined for common dolphins from this region. Therefore, the aims of the present study were to investigate the cranial maturation process, to assess the use of the degree of cranial suture fusion and developmental status of bones as indicators of cranial maturity, and to determine age at cranial maturity in *Delphinus* sp. from New Zealand waters.

MATERIALS AND METHODS

A total of 66 common dolphin skulls (males: 24, females: 34, unknown sex: 8), from stranded and bycaught individuals from New Zealand waters, were included in this study. Of those, 74.2% ($n = 49$) (males: 21, females: 28) were stored at Massey University, Auckland, and 25.8% ($n = 17$) skulls (males: 3, females: 6, unknown sex: 8) were housed at the Museum of New Zealand Te Papa Tongarewa, Wellington (Table S1). The intact *Delphinus* sp. heads archived frozen at Massey University required tissue removal prior to data collection (refer to Jordan 2012). Information on sex, reproductive developmental status (*i.e.*, sexually immature and mature), total body length (TBL), age, and location of the stranding or incidental capture were available from the New Zealand Common Dolphin Project (NZCDP) database (Massey University, unpublished data) for the majority of heads stored at Massey University, as well as for some museum specimens (summarized in Table S1). A Kruskal-Wallis test was run to determine whether median total body length (TBL) differed significantly with maturity status and sex. Age was estimated based on counting growth layer groups in dentine tissue (see Murphy *et al.* 2014 for an overview of the methodology).

Cranial Sutures

Data collection—The degree of fusion of 13 cranial suture lines and one joint were recorded from each skull, separately from both sides of the skull, as well as two cranial sutures that were median in position (Table 1; Fig. S1). Cranial sutures and the joint were selected based on previous odontocete studies, in which degree of cranial suture fusion had been employed as a maturity indicator or, the pattern of suture fusion had been investigated; such as Van Waerebeek (1993), González (2002), Chen *et al.* (2011), and Galatius *et al.* (2011). For the majority (sutures and a joint numbered 4 to 16 in Table 1), the degree of fusion was categorized using a scoring system differentiating four fusion stages: Stage A = no fusion, cranial bones can be moved freely; Stage B = limited fusion, bones cannot be moved, suture lines clearly visible at all points (adapted from Van Waerebeek 1993); Stage C = partial obliteration of suture line (adapted from Van Waerebeek 1993); and Stage D = complete obliteration of suture line (adapted from Galatius *et al.* 2011). Due to difficulties in identifying criteria such as “limited fusion” and “partial obliteration of suture line” for sutures numbered 1 to 3, only fusion stages A and D were used. Examples of the different stages of suture fusion of two selected sutures are displayed in Figure S2.

Table 1. List of cranial sutures (s) and one joint (j) assessed for cranial maturity status determination of *Delphinus* sp. skulls from New Zealand waters.

Number	Abbreviation	Side	Cranial sutures	Reference
1	max-fr	l/r	maxilla-frontal (s)	González 2002
2	premax-max	l/r	premaxilla-maxilla (s)	González 2002
3	na-fr	l/r	nasal-frontal (s)	González 2002
4	fr-fr	m	frontal-frontal (s)	González 2002
5	fr-in	l/r	frontal-interparietal (s)	González 2002
6	fr-or	l/r	frontal-orbitosphenoid (s)	Galatius <i>et al.</i> 2011
7	la-fr	l/r	lacrima-maxilla-frontal (s)	Van Waerebeek 1993
8	pa-ex	l/r	parietal-exoccipital (s)	Galatius <i>et al.</i> 2011
9	pa-fr	l/r	parietal-frontal (s)	Galatius <i>et al.</i> 2011
10	pal-max	l/r	palatine-maxilla (s)	Van Waerebeek 1993
11	pal-pal	m	palatine-palatine (s)	González 2002
12	pa-so	l/r	parietal-supraoccipital (s)	Galatius <i>et al.</i> 2011
13	pt-ba	l/r	pterygoid-basioccipital (j)	Van Waerebeek 1993
14	pt-pal	l/r	pterygoid-palatine (s)	Van Waerebeek 1993
15	so-ex	l/r	supraoccipital-exoccipital (s)	Chen <i>et al.</i> 2011
16	zy-pa-ex	l/r	zygomatic-parietal-exoccipital (s)	Van Waerebeek 1993

Note: l/r = left and right side of the skull, respectively; m = suture located along midline of the skull.

Data Analyses

Misclassification index—The use of the degree of fusion of individual sutures as an indicator for a dolphin's cranial maturity status was assessed through the calculation of a misclassification index (after Mead and Potter 1990). For this purpose, it was necessary to assess bilateral asymmetry in the degree of suture fusion (Chen *et al.* 2011) and also correlation with age (González 2002). To test for bilateral asymmetry, non-parametric Wilcoxon matched-pairs signed-rank tests were run for 13 sutures and one joint using suture scores recorded on both the left and right side of the skull (see Table 1, after Chen *et al.* 2011). The palatine-palatine (pal-pal) and frontal-frontal (fr-fr) sutures did not require assessment, given that both sutures were median in position.

Spearman's rank correlations were conducted for each suture and the joint to determine whether the degree of fusion was correlated with age. Estimated ages were available for 43 (males: 19, females: 24) dolphins and minimum ages for eight (males: 2, females: 6), and only skulls with estimated ages were included in the nonparametric test. It was necessary to pool some ages (6–7 yr, 8–9 yr, 10–11 yr, 12–14 yr, and 16–18 yr) due to small sample sizes, and since the degree of suture closure was not expected to differ substantially among the oldest skulls, dolphins aged ≥ 20 yr were also pooled, which allowed their inclusion ($n = 3$) in the analysis. The two oldest dolphins, both long-term captive dolphins, were ≥ 33 and ≥ 35 yr in age (see Murphy *et al.* 2014).

In order to calculate a misclassification index, it was necessary to preliminarily classify all skulls as either cranially immature or mature (Chen *et al.* 2011). Specimens were regarded as cranially mature if two of the criteria listed in Table 2 were met. The asymptotic TBLs for physical maturity had been estimated for male and female *Delphinus* sp. from New Zealand waters using the Gompertz growth model (KAS,

Table 2. Preliminary criteria for cranial maturity determination of *Delphinus* sp. skulls from New Zealand waters. Skulls were regarded as cranially mature if two or more criteria were met. TBL = total body length.

Sex	Criteria	Criteria description	Reference
Male	Cranial	Primary criteria: Fusion of premaxillae to maxillae ≥ 50% of the length of the rostrum	Jefferson and Van Waerebeek 2002
	Sexual	Testes assessed as sexually mature (evidence of spermatogenesis)	Perrin and Heyning 1993
	Physical	Secondary criteria: TBL ≥ 204.5 cm (asymptote) ≥ 12 yr of age	KAS, unpublished data Murphy <i>et al.</i> 2005
Female	Cranial	Primary criteria: Fusion of premaxillae to maxillae ≥ 50% of the length of the rostrum	Jefferson and Van Waerebeek 2002
	Sexual	Ovaries assessed as sexually mature (evidence of ovarian scars)	Perrin and Heyning 1993
	Physical	Secondary criteria: TBL ≥ 199.9 cm (asymptote) ≥ 9 yr of age	KAS, unpublished data Murphy and Rogan 2006

unpublished data). However, due to the limited sample size in that study, the assessment of the “maturity” status for dolphins in the current analysis was initially based on sexual maturity status and the degree of the premaxilla-maxilla fusion (following Perrin and Heyning 1993, Van Waerebeek 1993). If data on sexual maturity status were not available, the estimated asymptote values for TBL at physical maturity in male and female NZ common dolphins were used as secondary criteria (males: 204.5 cm, $n = 28$ females: 199.9 cm, $n = 42$; KAS, unpublished data). In the absence of data on age at physical maturity (APM) for *Delphinus* sp. in New Zealand waters, APM determined for male (11.9 yr; Murphy *et al.* 2005), and female (9 yr; Murphy and Rogan 2006) *D. delphis* from the eastern North Atlantic using growth models of TBL as a function of age were also used as secondary criteria, given that asymptotic lengths of both populations were comparable (males: 206.0 cm, $n = 170$, Murphy *et al.* 2005; females: 202.0 cm, $n = 510$, Murphy *et al.* 2009).

Following Chen *et al.* (2011), suture fusion stages A and B were classified as limited fusion (representative of immature dolphins) and fusion stages C and D were classified as advanced fusion (representative of mature dolphins). Based on these groupings, three misclassification indices, percentage of immatures misclassified, percentage of matures misclassified, and total percentage misclassified, were calculated for each suture and a joint (Mead and Potter 1990).

As the data set violated chi-square test assumptions, Fisher’s Exact tests were run independently for each cranial suture and one joint to assess whether degree of suture fusion (limited fusion *vs.* advanced fusion) differed significantly with maturity status.

Suture Index Computation

A scoring system, similar to that developed by Sivertsen (1954) for pinnipeds, was employed to compute a suture index (SI) with the aim to determine

a cut-off point for cranial maturity. For this purpose, fusion stages A (no fusion) and B (limited fusion) scored 0 and 0.5, respectively. Fusion stages C and D (advanced fusion, indicative of cranial maturity) were pooled and scored 1. Scores recorded on the left and right side of the cranium for a given suture were averaged for those sutures that did not display significant bilateral asymmetry. The SI for each skull was determined by calculating the sum of the averaged suture scores that: (1) were significantly correlated with age (adapted from González 2002), (2) displayed a significant difference in the degree of suture fusion between mature and immature skulls, and (3) for which all three misclassification indices were <50% (devised in this study). Given that the computed SI was based on count data, a nonparametric Mann-Whitney *U* test was applied to examine whether the median SI differed significantly between cranially immature and mature skulls. The lower limit of the interquartile range computed for mature skulls (8.0) was regarded as the cut-off point for cranial maturity given that interquartile ranges of the SI determined for immature and mature individuals did not overlap. The validity of this cut-off point to decipher cranial maturity status was tested through the calculation of a misclassification index. Spearman's rank correlations were carried out to determine whether the SI was correlated with dolphin age.

Premaxilla-maxilla Fusion

In order to assess the validity of premaxilla-maxilla fusion as a cranial maturity indicator for *Delphinus* sp. in New Zealand waters, the extent of fusion of the bones of the dorsal side of the rostrum, was classified according to five categories from the pointed tip of the jaws towards the base of the rostrum: Category 1 = less than 50% of the length of the rostrum; Category 2 = equal to 50% of the length of the rostrum; Category 3 = more than 50%, but less than 75% of the length of the rostrum; Category 4 = more than 75%, but less than base of rostrum; and Category 5 = to base of rostrum. Categories 1 to 2 and 5 were adapted from Jefferson and Van Waerebeek (2002) and Amaha (1994), respectively. Categories 3 and 4 were devised in the present study. Fusion to the distal end of the rostrum was not assessed, as it was deemed an unreliable indicator of cranial maturity in the common dolphin by Heyning and Perrin (1993). In addition, the category "fusion up to the end of the premaxilla fusion" was also not used, owing to the high individual variability in the length of premaxilla fusion noted by Amaha (1994).

Nonmetric Data

Data collection—Prior to undertaking nonmetric analysis, the cranial maturity status of each skull was reassessed using the new criteria identified from analysis of cranial SI data. Cranial maturity status was examined in three nonmetric characters in which "trait expression" were linked or likely linked to ontogeny: (1) IAS = degree of fusion of the interalveolar septa of maxillary and mandibular tooth rows (Tavares *et al.* 2010); (2) MNC = relative extension of the ascending process of the maxilla in relation to the nuchal crest; and (3) WMF = width of the maxilla relative to the frontals above the orbit (devised in the present study based on observations made on skulls with known sexual maturity status, refer to Table 3).

Table 3. Developmental status of nonmetric characters. For character abbreviation refer to Methods: *Data collection*.

Character	Cranially immature	Cranially mature	Reference
IAS	Partly developed	Fully developed	Tavares <i>et al.</i> 2010
WMF	Maxilla wider	Frontal wider	This study
MNC	Maxillae anterior to nuchal crest	Maxilla at or posterior to nuchal crest	This study

For analyses, all trait expressions allocated to immature and mature developmental status were coded as “1” and “2,” respectively. Examples of the different developmental stages are displayed in Figures S3 and S4.

Data Analyses

Bilateral nonmetric characters were tested for asymmetry in trait expression using the equation from Green *et al.* (1979):

$$\chi^2 = (b - c)^2 / (b + c)$$

where b = left presence only and c = right presence only.

Statistical significance was determined using the critical chi-square value for 1 degree of freedom (significant if $\chi^2 > 5$). Correlation between left and right sides for bilateral traits was assessed using the following equation from Green *et al.* (1979):

$$o = [(ad - bc)^2 / (a + b)(a + c)(b + d)(c + d)]^{1/2}$$

where a = bilateral presence, b = left presence only, c = right presence only, and d = bilateral absence. Bilateral nonmetric characters that displayed no significant asymmetry in trait expression and in which correlation between sides was ≥ 0.8 were represented by the left side of the skull only. Whereas, both sides were considered independently for all bilateral characters in which significant asymmetry in trait expression was detected. Chi-square tests between immature and mature skulls were conducted independently for each character to investigate whether trait expression was dependent of maturity status. Fisher’s Exact tests were run when any sample size was < 5 .

Three misclassification indices (percentage of immatures misclassified, percentage of matures misclassified, and total percentage misclassified) were calculated for each nonmetric character where skulls were regarded as “misclassified,” when displaying a trait expression representing the opposite maturity status (adapted from Mead and Potter 1990).

Tooth Wear

Tooth condition could only be assessed on the frozen intact heads stored at Massey University. The heads were defrosted for a minimum duration of 24 h and the general condition of each individual tooth in both the maxilla and mandible was recorded according to seven predefined categories: not erupted, partly erupted,

normal (fully intact), partly worn, worn to gum line, damaged, and missing (NZCDP, unpublished data).

Approximately 10 or more teeth, predominantly from the middle section of the lower left mandible, had been removed from the majority of skulls for age estimation prior to commencing recordings of tooth condition; and the mandibles of several dolphins were also missing. For consistency and to maximize the number of skulls to be included for analyses, statistical analyses were therefore based only on rostral teeth from both the right and left sides. Proportion of rostral teeth in each of the seven tooth condition categories was determined for each individual skull. Nonparametric Mann-Whitney tests were applied to determine whether the median percentage per tooth condition category differed significantly (P -value significant at $P > 0.05$) with maturity status and age class.

RESULTS

Cranial Sutures

Bilateral asymmetry—For 24.2% ($n = 16$) of skulls, the degree of suture fusion of one or more sutures (suture 1, $n = 7$; suture 2, $n = 4$; suture 3, $n = 4$; suture 6, $n = 1$) could not be determined owing to bone damage and the presence of dried flesh. As a result, sample sizes varied between the cranial sutures assessed. No significant difference ($P > 0.05$) was detected in the median degree of fusion between the left and right side for any of the sutures and the joint investigated ($n = 14$, Table 4).

Correlation with age—The degree of suture fusion was significantly ($P < 0.001$) and positively correlated with dolphin age, except for the supraoccipital-exoccipital

Table 4. Wilcoxon matched-pairs signed-ranks tests for bilateral asymmetry of the degree of fusion of cranial sutures and a joint (*) assessed on *Delphinus* sp. from New Zealand waters.

Cranial suture	n	%	W	P
fr-in	58	15.5	15	0.426
fr-or	65	0.0	0	n/a
la-fr	60	1.7	1	>0.999
max-fr	65	6.2	10	0.125
na-fr	66	7.6	3	0.813
pa-ex	61	8.2	-3	0.813
pa-fr	64	15.6	0	>0.999
pa-so	64	7.8	-5	0.625
pal-max	63	1.6	-1	>0.999
pre-max	66	13.6	-15	0.426
pt-ba*	63	14.3	-25	0.164
pt-pal	64	1.6	1	>0.999
so-ex	65	0.0	0	n/a
zy-pa-ex	64	20.3	7	0.839

Note: n = total number; % = percentage of pairs that differed in the degree of fusion between the right and left side for a given suture; W = sum of signed ranks, where positive and negative values indicate more advanced fusion on the right and left side of the skull, respectively; n/a = test was not conducted, because all pairs were equal. For suture abbreviation refer to Table 1.

Table 5. Spearman's rank correlation results for degree of suture fusion in relation to age for individual sutures of *Delphinus* sp. skulls from New Zealand waters.

Cranial suture	Spearman's rank correlation		
	<i>n</i>	coefficient (<i>r</i>)	<i>P</i>
fr-in	41	0.886	***
fr-fr	41	0.867	***
fr-or	41	0.754	***
la-fr	39	0.761	***
max-fr	42	0.654	***
na-fr	42	0.757	***
pa-ex	40	0.817	***
pa-fr	42	0.777	***
pa-so	42	0.729	***
pal-max	40	0.682	***
pal-pal	42	0.645	***
premax-max	42	0.633	***
pt-ba ^a	42	0.863	***
pt-pal	42	0.814	***
so-ex	40	0.271	0.091
zy-pa-ex	42	0.524	***

Note: *** = < 0.001. For suture abbreviation refer to Table 1.

^a = joint.

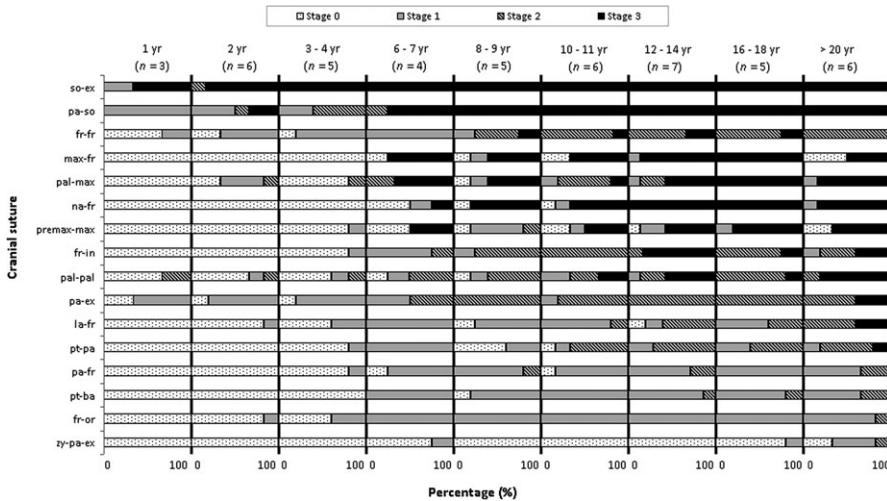


Figure 1. Degree of suture fusion, given as a percentage, by age class for 15 cranial sutures and one joint (pt-ba) recorded on *Delphinus* sp. skulls from New Zealand waters. Note: Stage A = bones can be moved freely, Stage B = no movement and suture lines clearly visible, Stage C = partial obliteration, Stage D = complete obliteration; yr = year. Dolphins aged 4–5 and 15–17 yr were not available for the present study. Sutures arranged according to trend of fusion with age class (top to bottom = early fusion, progressive but variable degree of fusion, and late fusion). For suture abbreviations refer to Table 1.

(so-ex) suture. Suture obliteration was recorded in so-ex suture in dolphins as young as one year old (Table 5; Fig. 1).

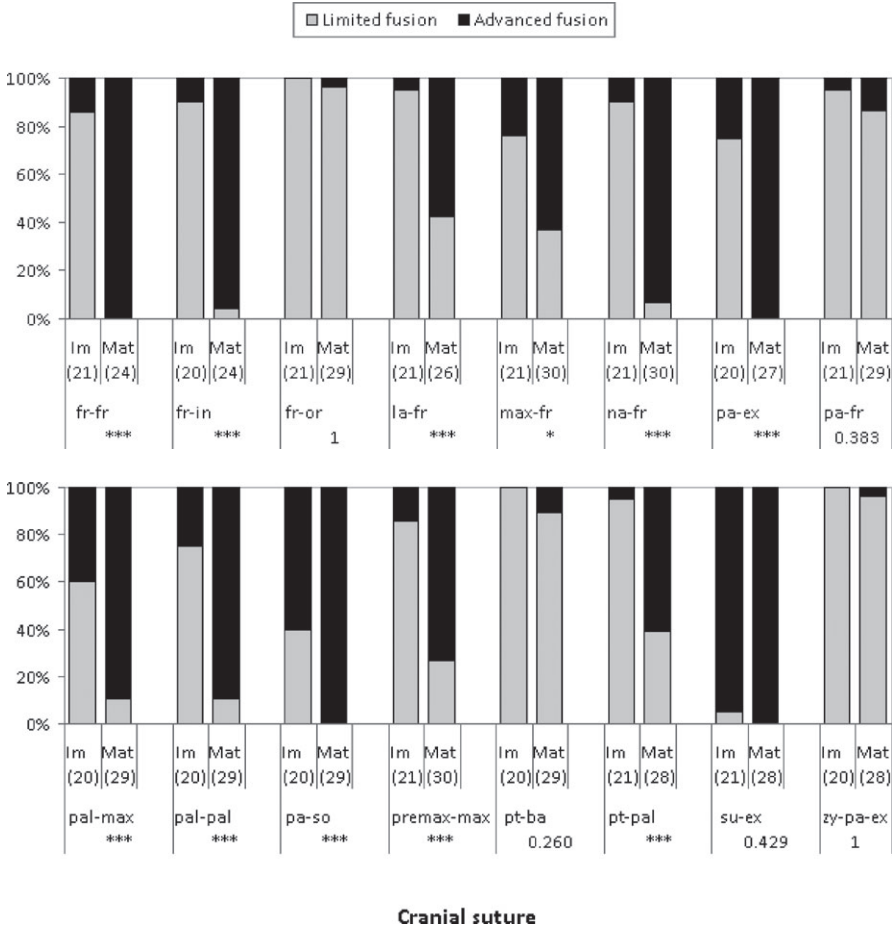
Although degree of suture closure was positively correlated with age in the remaining sutures ($n = 15$), the pattern of fusion was not uniform (refer to Table 5; Fig. 1). In two sutures (frontal-orbitosphenoid, fr-or; parietal-frontal, pa-fr) and the joint (pterygoid basioccipital, pt-ba), fusion stage D was never observed (dolphins aged 1 to ≥ 35 yr, $n = 47$). This indicated that complete obliteration of those suture lines and this joint may never occur. The zygomatic-parietal-exoccipital (zy-pa-ex) suture was characterized by delayed (partial) suture fusion, which occurred in only one individual aged ≥ 20 yr, and fusion stage D, complete obliteration of the suture line, which was never observed in the sample (Fig. 1). In contrast, early suture closure (partial/complete obliteration) of the so-ex and parietal-supraoccipital (pa-so) sutures occurred in 100% ($n = 6$) and 50% ($n = 3$), respectively, of dolphins of 2 yr of age. The remaining 10 sutures displayed a progressive, but variable, advance in the degree of suture fusion with age (Fig. 1). For example, complete obliteration was recorded in individuals aged 6–7 yr for four sutures (maxilla-frontal, max-fr; nasal-fr, na-fr; palatine-maxilla, pal-max, and premaxilla-maxilla, premax-max), while this suture fusion stage occurred only in dolphins aged ≥ 20 yr for the lacrimal-frontal (la-fr), pa-ex, and pterygoid-palatine (pt-pal) sutures.

Misclassification index—The degree of fusion in 68.8% ($n = 11$) of sutures investigated differed significantly ($P < 0.05$) between immature and mature skulls, with the latter having a more advanced degree of suture fusion (Fig. 2). A lack of significant difference in the degree of suture fusion between maturity categories in four sutures (fr-or, pa-fr, pt-ba, and zy-pa-ex) resulted from a very low percentage (3.3%–13.3%) of advanced degree of suture closure, characterized by partial or complete suture line obliteration, in mature skulls. Conversely, early suture closure, was recorded for the so-ex suture, with advanced stages of fusion documented in 95.7% ($n = 22$) of immature skulls, as observed in Figure 1.

The fr-fr and frontal-interparietal (fr-in) sutures displayed the lowest total misclassification index (6.6% and 6.8%, respectively) for immature and mature skulls combined (Table 6). Total misclassification of the remaining 13 sutures and the joint ranged from 7.8% (na-fr) to 56.3% (zy-pa-ex). Based on the criteria outlined earlier, 10 cranial sutures (fr-fr, fr-in, la-fr, max-fr, na-fr, pa-ex, pal-max, pal-pal, premax-max, and pt-pal), were deemed appropriate for the computation of the suture index (SI).

Suture Index

A SI (with no missing values for any suture) was calculated for 59.1% ($n = 39$) of the skulls preliminary categorized as cranially immature or mature. Median SI differed significantly (Mann Whitney U test: $U = 0.5$, $P < 0.001$) between both maturity categories. The median and range for the SI score for physically immature individuals was 1.8 and 0.0–7.0 ($n = 18$), respectively, and 8.5 and 7.0–10 ($n = 21$) in physically mature individuals. The interquartile ranges did not overlap (immature: 1.0–4.3, mature: 8.0–9.0). Agreement between “preliminary” cranial maturity status and cranial maturity status based on the SI was achieved for 97.4% ($n = 38$) of skulls, and only one cranially immature skull was misclassified as cranially mature.



Cranial suture

Figure 2. Percentage frequency of the degree of suture fusion (limited vs. advanced) of 15 cranial sutures and one joint (pt-ba) (listed alphabetically) for cranially immature (Im) and mature (Mat) *Delphinus* sp. skulls. Note: Limited fusion = fusion stages A and B, advanced fusion = fusion stages C and D, numbers in parentheses represent sample size. Fisher's Exact test results for differences in the state of suture fusion between skulls preliminary classified as cranially immature and mature are also given where: * = $P < 0.01$; *** = $P < 0.001$. For suture abbreviations refer to Table 1.

Age at Cranial Maturity

A SI was calculated for 35 individuals with estimated ages and six skulls with minimum ages. Overall, 42.9% ($n = 15$) and 57.1% ($n = 20$) of dolphins with estimated ages were male and female, respectively.

The SI was positively correlated with age in both sexes (Spearman's rank correlation, male: correlation coefficient = 0.901, $P \leq 0.001$, $n = 15$; female: correlation coefficient = 0.857, $P < 0.001$, $n = 20$). All dolphins with a calculated SI of ≥ 8 , were ≥ 11 yr of age (Fig. 3). The SI calculated for all aged dolphins that had preliminarily been classified as cranially mature was higher than those of

Table 6. Efficiency of individual sutures and a joint (*) as cranial maturity indicators for *Delphinus* sp. skulls from New Zealand waters. Determined by percentage misclassification for skulls preliminarily classified as cranially immature, cranially mature, and total misclassification (combined for cranially immature and mature). Sutures listed according to total percentage misclassified. For suture abbreviation refer to Table 1.

Cranial suture	Percentage (%) misclassified					
	Immature		Mature		Total	
	<i>n</i>	%	<i>n</i>	%	<i>n</i>	%
fr-fr	21	14.3	24	0.0	45	6.7
fr-in	20	10.0	24	4.2	44	6.8
na-fr	21	9.5	30	6.7	51	7.8
pa-ex	20	25.0	27	0.0	47	10.6
pal-pal	20	25.0	29	10.3	49	16.3
premax-max	21	14.3	30	26.7	51	21.6
pal-max	20	40.0	29	10.3	49	22.4
pt-pal	21	4.8	28	39.3	49	24.5
pa-so	20	60.0	29	0.0	49	24.5
la-fr	21	4.8	26	42.3	47	25.5
max-fr	21	23.8	30	36.7	51	31.4
su-ex	21	95.2	28	0.0	49	40.8
pa-fr	21	4.8	29	86.2	50	52.0
pt-ba*	20	0.0	29	89.7	49	53.1
fr-or	21	0.0	29	96.6	50	56.0
zy-pa-ex	20	0.0	28	96.4	48	56.3

immature individuals in all except one case (WS04-34Dd: female, 10 yr old, SI = 7.0, TBL = 189 cm in length).

Premaxilla-maxilla Fusion

Premaxilla-maxilla fusion in all individuals assessed as cranially mature (based on the SI only, see below; $n = 36$) was at least 50% the length of the rostrum (Fig. 4). None of the cranially immature skulls ($n = 30$) displayed premaxilla-maxilla fusion of $\geq 75\%$. All cranially immature skulls, in which premaxilla-maxilla fusion exceeded 50% of the length of the rostrum ($n = 5$), were approaching cranial maturity (based on age data and/or the SI scores).

Total Body Length

Median total body length (TBL) differed significantly with cranial maturity status (Kruskal-Wallis: $W = 28.110$, $df = 3$, $P < 0.001$). Dunn's multiple comparison *post hoc* test revealed that cranially mature individuals had significantly larger median TBL (male: median (interquartile range) = 212.5 (205.5–220.3) cm, range = 190.0–241.0 cm, $n = 8$; female: median (interquartile range) = 198.0 (195.0–206.0) cm, range = 187.0–212.0 cm, $n = 21$) than immatures of both sexes (male: median (interquartile range) = 174.0 (167.0–182.0) cm, range = 133.0–220.0 cm, $n = 13$; female: median (interquartile range) = 183.0 (177.4–189.0) cm, range = 159.0–189.5 cm, $n = 12$). No significant difference ($P > 0.05$) was detected in the median TBL between males and females. In total, 75.0% ($n = 6$) of cranially mature males, but only 47.6%

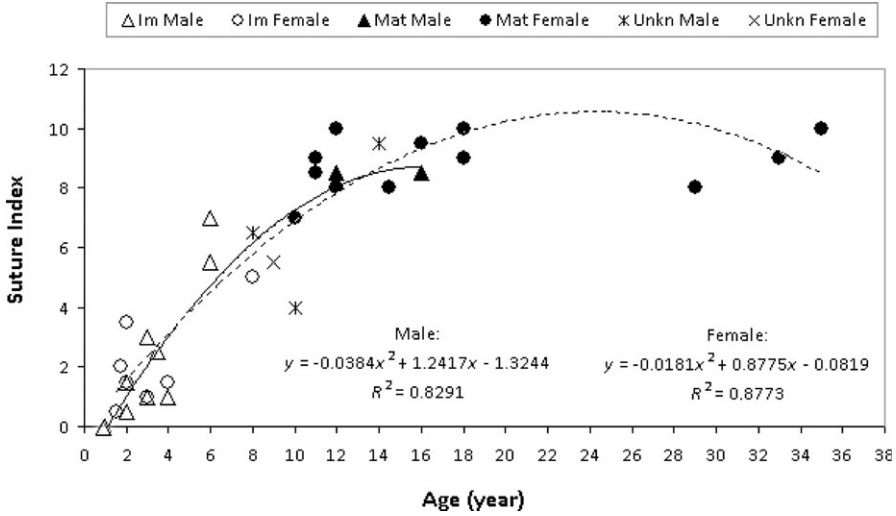


Figure 3. Suture index plotted against age (years) for *Delphinus* sp. skulls from New Zealand water, by sex and maturity status. Note: Im = cranially immature, Mat = cranially mature and unkn = of unknown cranial maturity status. Lines of best fit represent simple 2 polynomial lines for both the male (undamaged) and female (dashed) data sets.

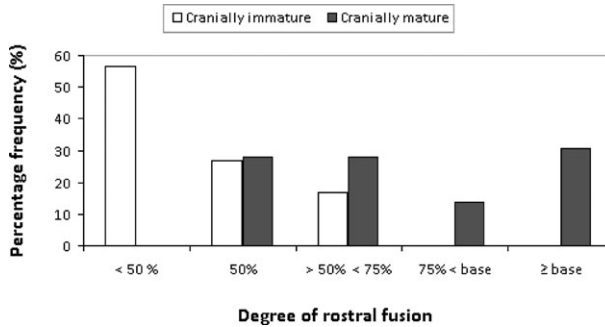


Figure 4. Percentage frequency of five different degrees of premaxilla-maxilla fusion by cranial maturity status (based on the suture index; immature: $n = 30$, mature: $n = 36$) for *Delphinus* sp. from New Zealand waters. Note: percentages represent extent of fusion over the length of the rostrum from the tip; base = base of rostrum.

($n = 10$) of mature females had TBLs equal to or greater than the asymptotic value for physical maturity reported by KAS (unpublished data; asymptote: males: 204.5 cm, females: 199.9 cm). Two cranially immature males (WS05-06Dd: 10 yr, SI = 4.0, TBL = 214.0cm and KS09-13Dd: 8 yr, SI = 6.5, TBL = 220.0 cm) had TBLs above the asymptote.

Reassessment of Cranial Maturity Status of Individual Skulls

Based on results obtained from the analysis of cranial SI data, the criteria for determining cranial maturity status were redefined. Skulls were regarded as cranially

mature if at least two of the following criteria were met: Criteria 1 = assessed as sexually mature; Criteria 2 = premaxilla-maxilla fusion equal to or greater than 75% of the length of the rostrum; Criteria 3 = SI equal to or greater than 8; and Criteria 4 = aged at 11 yr or older (as determined from growth layer groups in dentine tissue; see Murphy *et al.* 2014). Asymptotic TBLs were no longer considered appropriate as secondary criteria, owing to the high percentage of cranially mature females that were below 199.9 cm in length (refer to previous section). Cranial maturity status of each skull was reassessed using the new criteria prior to undertaking nonmetric analysis.

Nonmetric Data

The interalveolar septa (IAS) of the upper and lower jaws, as well as left and right sides of the skull were identical in all individuals investigated. Consequently, one tooth row, the left maxillary, was chosen to represent the developmental status of the IAS for a given individual. Asymmetric trait expression was recorded in the advancement of the maxillae relative to the nuchal crest (MNC). Trait expressions for this character was recorded significantly more often on the right side of the skull ($\chi^2 > 5$). Consequently, the correlation between sides was low (Table 7).

A significant difference ($P < 0.05$) in the developmental status between cranially immature and mature skulls was detected in all nonmetric characters assessed (IAS, WMF, and MNC) (Table 8). However, misclassification indices of the three characters indicated that only IAS was a relative reliable indicator of cranial maturity (see Table 9). Total misclassification of IAS was only 9.2% ($n = 6$), and all the misclassified individuals were dolphins that had been originally identified as cranially immature based on their SI score. (Table 9).

Tooth Wear

Tooth wear could only be assessed on intact *Delphinus* sp. heads archived frozen at Massey University ($n = 48$). Of those, 20.8% ($n = 10$) of skulls were excluded from analyses, because several teeth had been removed from the upper jaw or were missing due to bone damage. Cranially immature skulls ($n = 19$) had a significantly ($P < 0.001$) higher median percentage (88.4%) of normal teeth than mature skulls (12.8%, $n = 19$), while the latter had a significantly ($P < 0.01$) higher percentage of partly worn (52.0%) and damaged (4.8%) rostral teeth (Table 10). None of the immature dolphins had a tooth worn down to the gum line, while the maximum percentage of completely worn teeth in mature individuals was 11.0% with a median percentage of 5.3%. There was no significant difference in percentages of unerupted teeth between maturity categories (Table 10).

Table 7. Comparison of occurrence frequency of trait expression between sides of bilateral nonmetric cranial characters. Note: -- = bilateral absence; +- = left presence and right absence; -+ = left absence and right presence; ++ = bilateral presence; χ^2 = difference between sides (Chi-square significant at >5 for 1 degree of freedom); ϕ = correlation between sides; values in bold = significance. For character abbreviation refer to Methods: *Data collection*.

Character	--	+-	-+	++	<i>n</i>	χ^2	ϕ
WMF	54	2	0	9	65	2.0	0.888
MNC	20	1	15	28	64	12.3	0.569

Table 8. Chi-square test results of developmental status in cranially immature (Im) and mature (Mat) *Delphinus* sp. skulls from New Zealand waters.

Character	Total <i>n</i>	<i>n</i> per developmental status		Chi-square	
		Im	Mat	χ^2 (df = 1)	<i>P</i>
IAS	65	22, 6	0, 37	FE	***
WMF	65	8, 20	0, 37	FE	***
MNC (L)	64	25, 4	18, 17	FE	***
MNC (R)	64	18, 11	11, 24	4.836	0.02

Note: (L) and (R) = left and right side of the skull, respectively; numbers separated by comma = where first number = number of individuals displaying an immature developmental status and second number = number of individuals displaying a mature developmental status; FE = Fisher’s Exact test, which was used when sample size in any cell was <5; values in bold = *P* < 0.05; ** = < 0.01; *** = < 0.001. For character abbreviation refer to Methods: *Data collection*.

Table 9. Efficiency of the developmental status of nonmetric characters as cranial maturity indicators for *Delphinus* sp. skulls from New Zealand waters, as determined by percentage misclassification for skulls assessed as cranially immature and mature, and total misclassification (combined for physically immature and mature dolphins).

Nonmetric character	Percentage (%) misclassified					
	Immature		Mature		Total	
	<i>n</i>	%	<i>n</i>	%	<i>n</i>	%
IAS	28	21.4	37	0	65	9.2
WMF	28	60.7	37	0	65	26.2
MNC (L)	29	13.8	35	51.4	64	34.4
MNC (R)	29	37.9	35	51.4	64	34.4

Note: (L) and (R) = left and right side of the skull, respectively; For character abbreviation refer to Methods: *Data collection*.

DISCUSSION

This is the first study to assess cranial maturity in *Delphinus* sp. inhabiting New Zealand waters. In all skulls assessed, sutures located on the occipital region of the braincase were the earliest to fuse (*i.e.* supraoccipital-exoccipital, so-ex; parietal-supraoccipital, pa-so; and parietal-exoccipital, pa-ex). Early fusion of those sutures was previously observed in common (González 2002) and Risso’s dolphins, *Grampus griseus* (Chen *et al.* 2011). In the present study, partial obliteration of the frontal-orbitosphe-noid (fr-or) and zygomatic-parietal-exoccipital (zy-pa-ex) sutures were only recorded in dolphins aged ≥ 18 yr, and complete obliteration of these sutures was never observed. This again is consistent with patterns of fusion observed in other odontocetes such as *Stenella* sp., in which fused suture lines related to the squamosal and orbit-osphenoid were only reported in some older, physically mature individuals (Perrin 1975). Likewise, Chen *et al.* (2011) observed that sutures on the lateral sides of the braincase of Risso’s dolphins only showed signs of fusion in some of the mature skulls investigated.

Table 10. Percentage frequency of rostral teeth per tooth condition category ($n = 7$) separately for cranially immature and mature *Delphinus* sp. skulls from New Zealand waters. Mann-Whitney U test results for differences with maturity status are also given.

Tooth condition	Immature ($n = 19$)		Mature ($n = 19$)		Mann Whitney U	
	Median (I.Q.R.)	Range	Median (I.Q.R.)	Range	U	P
Not erupted	0 (0–0.5)	0–9.1	0 (0–1.76)	0–38.3	154	0.437
Partly	2.4 (1.2–3.4)	0–7.5	1.1 (0.0–2.4)	0–13.1	112	0.047
Normal	88.6 (60.1–96.5)	17.1–97.9	12.8 (5.5–30.3)	0–91.8	31	***
Partly worn	2.3 (0.0–31.9)	0–68.3	52.0 (41.9–58.5)	3.5–91.7	85	***
Worn to gum	0 (0–0.0)	0.0–0.0	5.3 (2.7–11.3)	0–26.7	n/a	n/a
Damaged	0 (0.0–5.6)	0–24.4	4.8 (2.4–16.6)	0–53.6	88.5	**
Missing	0 (0–0.0)	0–1.2	0 (0.0–2.6)	0–17.3	125	0.037

Note: I.Q.R. = interquartile range; P -value in bold = ≤ 0.05 ; ** = < 0.01 ; *** = < 0.001 ; n/a = test could not be performed as standard deviation of immature data set was zero.

In the current study, misclassification of cranial maturity status based on individual sutures exceeded 50% in a quarter of all cranial sutures assessed (frontal-orbitosphenoid, fr-or; parietal-frontal, pa-fr; pterygoid-basioccipital, pt-ba; zygomatic-parietal-exoccipital, zy-pa-ex), and the degree of fusion of those sutures was, therefore, not indicative of maturity status. These findings concur with Perrin (1975) and González (2002), who also demonstrated that only part of all cranial sutures investigated displayed a consistent pattern of fusion with maturity status and age (e.g., 34.4% in *D. delphis*, González 2002). In the present study, the frontal-frontal (fr-fr) and frontal-interparietal (fr-in) sutures provided the lowest total percentage misclassification (6.7% and 6.8%, respectively). Similarly, fr-in suture was reported as the best indicator for assessing sexual maturity in Risso's dolphins (Chen *et al.* 2011). The degree of fusion of the nasal bones, the exoccipital bone, pterygoids, and the zygomatic process of squamosal were used for determining cranial maturity status in *Delphinus* skulls from the western South Atlantic (Brazil, Uruguay, and Argentina; Tavares *et al.* 2010). With the third lowest total percentage misclassification of 7.8%, degree of fusion of the nasal bones was also deemed a relatively good indicator of cranial maturity in the present study. Thus, the lowest total percentage misclassification in the present study was obtained for sutures located at the vertex of the skull (fr-fr, fr-in, and na-fr). Important muscle groups related to the nasal complex attached at the vertex region (Mead 1975), and the relative late fusion of sutures related to the breathing complex could be indicative of extended growth of this functional complex (González 2002). Fusion rate of these sutures was of intermediate status in the present study. However, this observation could be an artifact of small sample size.

The calculated suture index (SI) suggests that cranial maturity in *Delphinus* sp. from New Zealand waters is attained at approximately 11 yr of age (pooled for both sexes). This finding is comparable to the estimated age at cranial maturity (11 yr) in the *D. delphis* from Argentinean waters (González 2002). A life history study conducted on 39 female *D. delphis* from Japanese waters reported that 89.7% ($n = 35$) of sexually mature individuals were >9 yr of age (Takahashi *et al.* 2006), which is in line with what has been determined in other studies on *D. delphis* worldwide (e.g., Danil and Chivers 2007; Westgate 2007; Murphy *et al.* 2009). Given that growth

continues in odontocetes after attainment of sexual maturity (Chivers 2009), this indicates that cranial maturity may be attained at an older age than previously reported (approximately 5 yr) for Japanese *D. delphis* in Amaha (1994). The cut-off point for cranial maturity in the current study might be set very conservatively, due to the small sample size. Nonetheless, cranial maturity attainment at ca. 11 yr complies with the age at physical maturity (APM) proposed for female *D. delphis* in Irish waters (females attained asymptotic length at ca. 9 yr, based on the single Gompertz growth model; Murphy and Rogan 2006), and is similar to the estimated APM for male *D. delphis* in the larger eastern North Atlantic (12 yr, Murphy *et al.* 2005).

Length of premaxilla-maxilla fusion of all skulls regarded as cranially mature (based on the SI) was $\geq 50\%$ of the length of the rostrum (from the tip to the base), indicating that all skulls with premaxilla-maxilla fusion of $< 50\%$ have not yet attained cranial maturity and should be regarded as cranially immature. The finding that premaxilla-maxilla (premax-max) fusion along the rostrum was $> 50\%$ in 16.7% ($n = 5$) of skulls assessed as cranially immature highlights that this criterion was not a reliable indicator of cranial maturity. As none of the skulls assessed as cranially immature displayed fusion of $\geq 75\%$ of the rostrum, *Delphinus* sp. skulls from New Zealand waters with premaxilla-maxilla fusion of $\geq 75\%$ can be regarded as cranially mature. Interestingly, the extent of premaxilla-maxilla fusion at cranial maturity in New Zealand skulls is substantially less than Japanese *D. delphis*, where "premaxilla-maxilla fusion up to the base of the rostrum" (over the entire length of the dorsal aspect of the rostrum) indicated cranial maturity. However, as both the rate and extent of premax-max fusion can differ between *Delphinus* sp. populations (Amaha 1994), this might account for the differences observed between both studies. *Delphinus* sp. off New Zealand attain a larger skull size (maximum CBL = 494.9 mm; Jordan 2012) compared to *D. delphis* off Japan (457.3 mm; Amaha 1994), and differences in skull size might influence degree and extent of rostral fusion, though this would require further investigation.

In the present study, none of the three nonmetric characters assessed were found to be absolute indicators of cranial maturity in New Zealand *Delphinus* sp. The lowest misclassification was obtained for the developmental status of interalveolar septa (IAS) in the left maxillary tooth row (IAS; 9.2%). IAS was previously employed in determining cranial maturity status in *Delphinus* inhabiting the western South Atlantic Ocean, where fully developed septa were regarded as an indication for maturity (Tavares *et al.* 2010). However, while IAS were fully developed in all mature skulls in the present study (misclassification of 0.0%), 21.4% ($n = 6$) of cranially immature individuals also displayed fully developed septa and were misclassified as cranially mature. Given that the SI suggested that cranial maturity is not attained until at least 11 yr of age, it is not surprising that the IAS of some skulls in the current study were fully developed before the onset of cranial maturity.

Preliminary findings suggest that tooth condition could, to some degree, be used as a cranial maturity indicator. As expected, cranially immature dolphins had a significantly higher percentage (88.6%) of normal (fully intact) teeth as compared to mature dolphins (12.8%), while the latter had a significantly higher percentage of partly worn (52.0%) and damaged (4.8%) teeth. Presence of fully worn rostral teeth provided evidence for cranial maturity, as no immature dolphin possessed teeth that were worn down to the gum line. The youngest dolphin with fully worn (one or more) teeth was 12 yr of age (KS08-09Dd). Degree of tooth wear has been employed as an aging technique in several terrestrial mammals (Morris 1972). However, owing to individual variation in tooth wear and interobserver bias, precision of this method

is limited (Robinson 1979). In the present study, small sample sizes prevented analyses of tooth wear related to age classes and such research, therefore, warrants further investigation.

Results presented here suggest that New Zealand *Delphinus* sp. skulls should be regarded as cranially mature if at least two of the following criteria are met: Criteria 1 = assessed as sexually mature; Criteria 2 = premaxilla-maxilla fusion equal to or greater than 75% of the length of the rostrum; Criteria 3 = SI equal to or greater than 8; and Criteria 4 = aged at 11 yr or older (as determined from growth layer groups in dentine tissue). Until further data becomes available, asymptotic TBLs should not be considered when assessing cranial maturity status. Although sample sizes were small, Jordan (2012) recommended that, in the interim until further work is undertaken, New Zealand *Delphinus* sp. should be regarded as a large form of *D. delphis*. This was based on assessments of taxonomic status using rostrum length to zygomatic width ratios (RL/ZW = 1.49, 1.39–1.61 range, $n = 21$), the Kalya Index (108.1, 100.3–125.6, $n = 58$) and tooth counts (left maxillary: 50, 45–55, $n = 19$). Thus, the criteria outlined above could be used to assess cranial maturity status in studies undertaken on other geographic populations of *D. delphis*.

ACKNOWLEDGMENTS

The authors thank Department of Conservation and Massey University staff whom assisted with carcass recoveries or assisted with postmortem examinations. Special thanks extend to Karl McLeod, Martin Stanley, Steph Watts, Phil Brown, Thelma Wilson, Rory Renwick (DOC) and Padraig Duignan, Mana Stratton, Wendi Roe, Gareth Jones, Laureline Meynier, Monica Bando, Mike Hogan, Sonja Clemens, and the many C-MRG postgraduates (MU), all of whom have contributed significantly. We acknowledge Rochelle Constantine (University of Auckland) for molecular sex determination conducted on one of the carcasses and Tangata Whenua for supporting the postmortem investigations by allowing short-term retention of the crania for ongoing scientific investigation. We wish to thank Ewan Fordyce, Wendi Roe, Andrew Westgate, and an anonymous reviewer for their comments on previous drafts of this manuscript. Research was conducted under research permits RNW/22/2003/182 and RNW/HO/2008/03 issued to KAS by the New Zealand Department of Conservation. SM was supported by a Marie Curie International Outgoing Fellowship within the Seventh European Community Framework Programme.

LITERATURE CITED

- Amaha, A. 1994. Geographic variation of the common dolphin, *Delphinus delphis* (Odontoceti: Delphinidae). Ph.D. thesis, Tokyo University of Fisheries, Tokyo, Japan. 211 pp.
- Amaral, A. R., L. B. Beheregaray, K. Bilgmann, *et al.* 2012a. Seascape genetics of a globally distributed, highly mobile marine mammal: the short-beaked common dolphin (*Delphinus*). PLOS ONE 7:e31482.
- Amaral, A., L. Beheregaray, K. Bilgmann, *et al.* 2012b. Influences of past-climate changes on historical population structure and demography of a cosmopolitan marine predator, the common dolphin (genus *Delphinus*). Molecular Ecology 21:4854–4871.
- Bell, C. H., C. M. Kemper and J. G. Onran. 2002. Common dolphins *Delphinus delphis* in Southern Australia: A morphometric study. Australian Mammalogy 24:1–10.
- Calzada, N., A. Aguilar, C. Lockyer and E. Grau. 1997. Patterns of growth and physical maturity in the western Mediterranean striped dolphin, *Stenella coeruleoalba* (Cetacea: Odontoceti). Canadian Journal of Zoology 75:632–637.

- Chen, I., L. S. Chou, Y.-J. Chen and A. Watson. 2011. The maturation of skulls in postnatal Risso's dolphins (*Grampus griseus*) from Taiwanese waters. *Taiwania* 56:177–185.
- Chivers, S. J. 2009. Cetacean life history. Pages 215–220 in W. F. Perrin, B. Würsig and J. G. M. Thewissen, eds. *Encyclopedia of marine mammals*. 2nd edition. Academic Press, San Diego, CA.
- Dailey, M. A., and W. F. Perrin. 1973. Helminth parasites of porpoises of the genus *Stenella* in the Eastern Tropical Pacific, with descriptions of two new species: *Mastigonema stenellae* gen. et sp. n. (Nematoda: Spiruroidea) and *Zulophotrema pacificum* sp.n.n (Trematoda: Digenea). *Fisheries Bulletin* 71:455–471.
- Danil, K., and S. J. Chivers. 2007. Growth and reproduction of female short-beaked common dolphins, *Delphinus delphis*, in the eastern tropical Pacific. *Canadian Journal of Zoology* 85:108–121.
- Di Natale, A., and A. Mangano. 1983. Biological distribution: New data on the sperm whale, *Physeter macrocephalus* L., in the central Mediterranean Sea. *Rapports et Procès-Verbaux des Réunions Conseil Permanent International pour L'Exploration de la Mer* 28:183–184.
- Evans, W. E. 1994. Common dolphin, white-bellied porpoise, *Delphinus delphis*, Linnaeus, 1758. Pages 191–224 in S. H. Ridgway and R. Harrison, eds. *Handbook of marine mammals*, 1st edition. University Press, London, U.K.
- Fordyce, R. E. 2009. Cetacean evolution. Pages 201–207 in W. F. Perrin, B. Würsig and J. G. M. Thewissen, eds. *Encyclopedia of marine mammals*, 2nd edition. Academic Press, San Diego, CA.
- Galatius, A., A. Berta, A. S. Frandsen and R. N. P. Godall. 2011. Interspecific variation of ontogeny and skull shape among porpoises (Phocoenidae). *Journal of Morphology* 272:136–148.
- González, P. M. 2002. Crecimiento y desarrollo corporal en delfines comunes (*Delphinus delphis* Linnaeus, 1758) del Mar Argentino [Growth and body development in common dolphins (*Delphinus delphis* Linnaeus, 1758) from the Argentine Sea]. M.Sc. thesis, Universidad Nacional de Mar del Plata, Mar del Plata, Argentina. 113 pp.
- Green, R. F., J. M. Suchey and D. V. Gokhale. 1979. The statistical treatment of correlated bilateral traits in the analysis of cranial material. *American Journal of Physical Anthropology* 50:629–634.
- Heyning, J. E., and G. M. Lento. 2002. The evolution of marine mammals. Pages 38–72 in A. R. Hoelzel, ed. *Marine mammal biology: An evolutionary approach*. 1st edition. Blackwell Publishing, Oxford, U.K.
- Heyning, J. E., and W. F. Perrin. 1994. Evidence for two species of common dolphin (Genus *Delphinus*) from the eastern North Atlantic. *Los Angeles County Museum of Natural History Contributions in Science* 442:1–35.
- Jefferson, T. A., and K. Van Waerebeek. 2002. The taxonomic status of the nominal dolphin species *Delphinus tropicalis* van Bree, 1971. *Marine Mammal Science* 18:787–818.
- Jefferson, T. A., S. Leatherwood and M. A. Webber. 1993. *Marine mammals of the world. FAO Species Identification Guide. Food and Agriculture Organization*, Rome, Italy.
- Jordan, F. F. J. 2012. Skull morphometry of the common dolphin, *Delphinus* sp., from New Zealand waters. M.Sc. thesis, Massey University, Auckland, New Zealand. 242 pp.
- Mead, J. G. 1975. Anatomy of the external nasal passages and facial complex in the Delphinidae (Mammalia: Cetacea). *Smithsonian Contributions to Zoology* 207:1–72.
- Mead, J. G., and C. W. Potter. 1990. Natural history of bottlenose dolphins along the central Atlantic coast of the United States. Pages 165–195 in S. Leatherwood and R. R. Reeves, eds. *The bottlenose dolphin*. Academic Press, San Diego, CA.
- Morris, P. 1972. A review of mammalian age determination methods. *Mammal Review* 2:69–104.
- Murphy, S., and E. Rogan. 2006. External morphology of the short-beaked common dolphin *Delphinus delphis*: Growth, allometric relationships and sexual dimorphism. *Acta Zoologica* 87:315–329.

- Murphy, S., A. Collet and E. Rogan. 2005. Mating strategy in the male common dolphin (*Delphinus Delphis*): What gonadal analysis tells us. *Journal of Mammalogy* 86:1247–1258.
- Murphy, S., J. S. Herman, G. J. Pierce, E. Rogan and A. C. Kitchener. 2006. Taxonomic status and geographical cranial variation of common dolphins (*Delphinus*) in the eastern North Atlantic. *Marine Mammal Science* 22:573–599.
- Murphy, S., A. Winship, W. Dabin, *et al.* 2009. Importance of biological parameters in assessing the status of *Delphinus delphis*. *Marine Ecology Progress Series* 388:273–291.
- Murphy, S., M. Perrott, J. McVee, F. Read and K. A. Stockin. 2014. Deposition of growth layer groups in dentine tissue of captive common dolphins *Delphinus delphis*. NAMMCO Scientific Publication Volume 10: Age estimation of marine mammals with a focus on monodontids. Available at <http://dx.doi.org/10.7557/3.3017>.
- Perrin, W. F. 1975. Variation of spotted and spinner porpoise (genus *Stenella*) in the eastern Pacific and Hawaii. *Bulletin of the Scripps Institution of Oceanography* 21:1–212.
- Perrin, W. F., and J. E. Heyning. 1993. Rostral fusion as a criterion of cranial maturity in the common dolphin *Delphinus delphis*. *Marine Mammal Science* 9:195–197.
- Robinson, P. T. 1979. A literature review of dental pathology and aging by dental means in nondomestic animals: Part I. *The Journal of Zoo Animal Medicine* 10:57–65.
- Rommel, S. 1990. Osteology. Pages 29–49 in S. Leatherwood and R. R. Reeves, eds. *The bottlenose dolphin*. Academic Press, San Diego, CA.
- Rosel, P. E., A. E. Dizon and J. E. Heyning. 1994. Genetic analysis of sympatric morphotypes of common dolphins (genus *Delphinus*). *Marine Biology* 119:159–167.
- Sivertsen, E. 1954. A survey of the eared seals (Family Otariidae) with remarks on the Antarctic seals collected by M/K “Norvegia” in 1928–1929. *Scientific Results of the Norwegian Antarctic Expedition* 36:1–76.
- Stewardson, C. L., T. Prvan, M. A. Meyer, S. Swanson and R. J. Ritchie. 2011. Suture index as an indicator of chronological age in the male South African fur seal, *Arctocephalus pusillus* (Pinnipedia: Otariidae). *In Proceedings of the Linnean Society of New South Wales* 132. p. 145.
- Stockin, K. A. 2008. The New Zealand common dolphin (*Delphinus* sp.): Identity, ecology and conservation. Ph.D. thesis, Massey University, Auckland, New Zealand. 235 pp.
- Stockin, K. A., A. R. Amaral, J. Latimer, D. M. Lambert and A. Natoli. 2014. Population genetic structure and taxonomy of the common dolphin (*Delphinus* sp.) at its southernmost range limit: New Zealand waters. *Marine Mammal Science* 30:44–63.
- Takahashi, Y., S. Ohwada, K. Watanabe, Y. Ropert-Coudert, R. Zenitani, Y. Naito and T. Yamaguchi. 2006. Does elastin contribute to the persistence of corpora albicantia in the ovary of the common dolphin (*Delphinus delphis*)? *Marine Mammal Science* 22:819–830.
- Tavares, M., I. B. Moreno, S. Siciliano, D. Rodríguez and M. C. de O Santos and M. E. Fabián. 2010. Biogeography of common dolphins (genus *Delphinus*) in the southwestern Atlantic Ocean. *Mammal Review* 40:40–64.
- Van Waerebeek, K. 1993. Geographic variation and sexual dimorphism in the skull of the dusky dolphin, *Lagenorhynchus obscurus* (Gray, 1828). *Fishery Bulletin* 91:754–774.
- Walker, W. A., S. Leatherwood, K. R. Goodrich, W. F. Perrin and R. K. Stroud. 1986. Geographical variation and biology of the Pacific white-sided dolphin, *Lagenorhynchus obliquidens*, in the north-eastern Pacific. Pages 411–465 in M. M. Bryden and R. R. Reeves, eds. *Research on dolphins*. Oxford University Press, Oxford, U.K.
- Westgate, A. J. 2007. Geographic variation in cranial morphology of short-beaked common dolphins (*Delphinus delphis*) from the North Atlantic. *Journal of Mammalogy* 88:678–688.

Received: 27 February 2014

Accepted: 9 December 2014

SUPPORTING INFORMATION

The following supporting information is available for this article online at <http://onlinelibrary.wiley.com/doi/10.1111/mms.12229/supinfo>.

Figure S1. Selection of cranial sutures and a joint (pt-ba) for cranial maturity determination in *Delphinus* sp. skulls from New Zealand waters in dorsal (top left), lateral (top right), occipital (middle left) and ventral (middle right and bottom) view. For suture and joint abbreviation refer to Table 1.

Figure S2. Examples of the different degrees of suture fusion (A–D) of the pterygoid-palatine and palatine-palatine sutures of *Delphinus* sp. from New Zealand waters. Note: Top left = stage A; top right = stage B; bottom left = stage C; bottom right = stage D.

Figure S3. Examples of the ontogenetic stages 1 (left) and 2 (right) of the nonmetric WMF (width of the maxilla relative to the frontal) recorded on *Delphinus* sp. from New Zealand waters. Note: max = maxilla; fr = frontal. Area of interest indicated by ellipse.

Figure S4. Examples of the developmental stages 1 (left) and 2 (right) of the nonmetric character IAS (interalveolar septa) recorded on the rostrum of *Delphinus* sp. from New Zealand waters.

Table S1. List of *Delphinus* sp. skulls from New Zealand waters included in the present study.